

MELANOMA CARE OPTIONS™

DECEMBER 2007

DERMATOLOGY EDITION

Contributing Authors



Lawrence E. Flaherty, MD, Editor



Clara Curiel-Lewandrowski, MD, Author



Mohammed Kashani-Sabet, MD, Author



David W. Ollila, MD, Author



Merrick I. Ross, MD, FACS, Author
Steering Committee Editor
Working Group Leader

Issue 3: Treatment of Melanoma in Special Circumstances

Editor's note . . .

This issue of *Melanoma Care Options*, the third in our 3-part series, focuses on the management of melanoma in special circumstances. The four cases presented here discuss issues specific to melanoma during pregnancy, in-transit melanoma, melanoma with an unknown primary site, and head and neck melanoma. In most cases, data from randomized, controlled clinical trials are not available to guide the management of melanoma in special circumstances, so the clinician must rely on clinical experience and the available literature. The faculty presents decision points related to medical oncology, surgical oncology, and radiation oncology, and provides recommendations and a review of clinical research findings relevant to these choices. Discussions of these

medical issues are complemented by a section on barriers to care, which contains insights into everyday issues faced by practitioners. The opinions herein are those of the authors. They are based on currently available data and clinical experience, and may change as new findings emerge.

As faculty editor of *Melanoma Care Options*, I would like to thank you for taking the time to read this newsletter series. I look forward to your input and I welcome your thoughts regarding the management of the cases described in this publication.

Sincerely,

LAWRENCE E. FLAHERTY, MD
Melanoma Care Coalition

A Note From the Chairmen/Steering Committee Editor

Welcome to the third issue of the 2007 *Melanoma Care Options* publication series from the Melanoma Care Coalition. We are pleased that the Melanoma Care Coalition's innovative interdisciplinary programming recently won the 2007 Alliance for Continuing Medical Education Award for Outstanding CME Collaboration. The first issue of the 2007 series focused on the diagnosis and profiling of melanoma, and the second issue highlighted therapeutic options. Our third issue pulls together information from both of these topics in examining case studies of melanoma in special circumstances, an area that is often controversial because of the lack of firm data and evidence-based guidelines. Included in this issue you will also find a section on barriers to care that affect melanoma management in the fields of dermatology, medical oncology, and surgical oncology. We hope that this content provides an appropriate background to the ongoing evaluation of these issues and stimulates discussion concerning the optimal management of special cases of melanoma. As always, we welcome your remarks on the series and we encourage you to participate in other Melanoma Care Coalition programs—see www.melanomacare.org for other Melanoma Care Coalition offerings. Thank you for participating in this interdisciplinary dialogue, which promises to improve our ability to care for patients.

Sincerely,

JOHN M. KIRKWOOD, MD
Co-Chair, Melanoma Care Coalition
Steering Committee

MERRICK I. ROSS, MD, FACS
Steering Committee Editor/Working Group Leader
Co-Chair, Melanoma Care Coalition
Steering Committee

Continuing Medical Education Information

Instructions for participation

- Read the case presentation and comments in the newsletter
- Complete the posttest questions and evaluation form at the end of the newsletter and fax or mail them to our office

To receive a maximum of 1.5 AMA PRA Category 1 Credits™ for this activity:

- Within 4 weeks of successful completion, you may access your credit transcript at <http://cchehs.upmc.edu/>
- 70% of your posttest answers must be correct for you to receive a certificate of credit

To receive up to 1.5 CNE credits for this activity:

- Within 4 weeks of successful completion, a certificate will be mailed to the address provided
- 70% of your posttest answers must be correct for you to receive a certificate of credit

Target Audience

This activity is directed toward dermatologists, dermatologic surgeons, surgical oncologists, medical oncologists, general surgeons, oncology nurses, primary care physicians, and other health care professionals who treat or screen for melanoma.

Statement of Need

Many cases of melanoma fall outside the mainstream situations covered by evidence-based guidelines. The appropriate management of these cases requires a careful evaluation of available literature and an understanding of special circumstances that may influence diagnosis, staging, lymph node biopsy, and surgical and nonsurgical therapeutic options. This publication presents 4 cases of melanoma in special circumstances (melanoma during pregnancy, in-transit melanoma, melanoma with an unknown primary, and head and neck melanoma) and addresses controversies in the staging and treatment of these cases. A review of relevant literature, with a focus on recent publications, and faculty recommendations are provided to help guide practitioners in choosing the optimal management strategies for melanoma patients with special circumstances.

Learning Objectives

After completing this activity, the participants will be able to:

- Address treatment issues in melanoma with complicating features or special circumstances, including pregnancy, in-transit melanoma, unknown primaries, or head and neck melanoma
- Discuss the diagnostic pitfalls and available treatment modalities for melanoma in pregnant women
- Describe the prognostic features and available treatment options for melanomas in problematic sites, including in-transit melanoma, head and neck melanoma, melanoma in pregnant patients, and metastatic melanoma with unknown primary origin
- Compare and contrast the prognostic features of melanoma with unknown primary versus other types of metastatic melanoma

Speakers & Disclosures:

Clara Curriel-Lewandrowski, MD
Assistant Professor of Dermatology
University of Arizona
Tucson, Arizona
No financial relationships to disclose

Lawrence E. Flaherty, MD
Professor of Medicine and Oncology
Karmanos Cancer Institute
Wayne State University
Detroit, Michigan
Grants/Research Support: Schering-Plough Corporation, Chiron Therapeutics, Celgene, Bayer; Consultant: Bayer; Speakers' Bureaus: Schering-Plough Corporation, GlaxoSmithKline

Mohammed Kashani-Sabet, MD
Associate Professor of Dermatology
Director, Melanoma Center
UCSF Cancer Center
University of California San Francisco School of Medicine
San Francisco, California
Consultant: Schering-Plough; Speakers' Bureau: Schering-Plough Corporation.

Ashfaq A. Marghoob, MD, FAAD
Associate Professor of Dermatology
Memorial Sloan-Kettering Cancer Center
Hauppauge, New York
No financial relationships to disclose

Date of Original Release: December 15, 2007

Expiration Date: December 15, 2008

Date of last review: December 15, 2007

Thomas E. Olencik, DO
Clinical Professor
Division of Hematology/Oncology
James Cancer Hospital and Solove Research Institute
Ohio State University
Columbus, Ohio
Speakers' Bureaus: Schering-Plough Corporation

David W. Ollila, MD
Associate Professor of Surgery
Director, Multidisciplinary Melanoma Program
University of North Carolina School of Medicine
Chapel Hill, North Carolina
No financial relationships to disclose

Douglas S. Reintgen, MD
Director
Lakeland Regional Cancer Center
Lakeland, Florida
Speakers' Bureau: Schering Oncology

Merrick I. Ross, MD, FACS
Professor of Surgical Oncology
University of Texas M.D. Anderson Cancer Center
Houston, Texas
Speakers' Bureaus: Schering-Plough Corporation, Genentech, Inc.

Steering Committee

John M. Kirkwood, MD (Co-Chair)

Director, Melanoma and Skin Cancer Program
University of Pittsburgh Cancer Institute
Professor and Vice Chairman for Clinical Research
Department of Medicine
University of Pittsburgh School of Medicine
Pittsburgh, Pennsylvania
Grants/Research Support: Schering-Plough Corporation, Berlex Laboratories, Pfizer Inc; Consultant: Antigenics Inc, MedImmune, Inc; Speakers' Bureau: Schering-Plough Corporation

Merrick I. Ross, MD, FACS (Co-Chair)*

Professor of Surgical Oncology
University of Texas M.D. Anderson Cancer Center
Houston, Texas
Speakers' Bureaus: Schering-Plough Corporation, Genentech, Inc.

Rosemary Giuliano, ARNP, MSN*

Surgical First Assistant
Morton Plant North Bay Hospital
New Port Richey, Florida
Speakers' Bureau: Schering-Plough Corporation

Susan M. Swetter, MD

Associate Professor of Dermatology
Director, Pigmented Lesion & Cutaneous
Melanoma Clinic
Stanford University Medical Center/VA Palo Alto Health
Care System
Co-Director, Stanford Multidisciplinary
Melanoma Clinic
Stanford, California
Speakers' Bureau: Schering-Plough Corporation

Publisher

PharmAdura, LLC
523 Route 303
Orangeburg, NY 10962
publisher@pharmadura.com

Managing Editor

Joseph Burns
No financial relationships to disclose

Art Director

Laurie Lohne, Creative MediaWorks
No financial relationships to disclose

Scientific Directors

Mike Coco, PhD
No financial relationships to disclose
Sharon L. Cross, PhD
No financial relationships to disclose

This newsletter is published by PharmAdura, LLC, Orangeburg, NY.

© PharmAdura, 2007. This newsletter may not be reproduced in whole or in part without the express written permission of PharmAdura, LLC.

This CME program represents the views and opinions of the individual faculty for each case and does not constitute the opinion or endorsement of the editors, the advisory board, the publishing staff, PharmAdura, the UPMC Center for Continuing Education in the Health Sciences, UPMC/University of Pittsburgh Medical Center or affiliates, or University of Pittsburgh School of Medicine.

Reasonable efforts have been taken to present educational subject matter in a balanced, unbiased fashion and in compliance with regulatory requirements. However, each activity participant must always use his or her own personal and professional judgment when considering further application of this information, particularly as it may relate to patient diagnostic or treatment decisions, including without limitation, FDA-approved uses, and any off-label uses.

Faculty

Bruce J. Averbook, MD

Associate Professor of Surgery
Metro Health Medical Center
Case Western Reserve University
Cleveland, Ohio
Speakers' Bureau: Schering Oncology Biotech

Matthew T. Ballo, MD

Associate Professor of Radiation Oncology
University of Texas M.D. Anderson Cancer Center
Houston, Texas
No financial relationships to disclose

Ernest C. Borden, MD

Director
Center for Cancer Drug Discovery & Development
Cleveland Clinic Cancer Center and Lerner Research Institute
The Cleveland Clinic Foundation
Cleveland, Ohio
Consultant: Cleveland Biolabs; Speakers' Bureaus: Novartis Pharmaceuticals Corporation, Pfizer Inc

Tania Bridgeman, RN, PhD

Director of Clinical Path Development
University of California, Irvine Medical Center
Orange, California
No financial relationships to disclose

Clara Curiel-Lewandrowski, MD*

Assistant Professor of Dermatology
University of Arizona
Tucson, Arizona
No financial relationships to disclose

David E. Elder, MB, ChB, FRCPA

Professor of Pathology & Laboratory Medicine
Hospital of the University of Pennsylvania
Philadelphia, Pennsylvania
Grants/Research Support: NIH/NCI, EU Framework

Marc S. Ernstoff, MD

Professor of Medicine
Dartmouth-Hitchcock Medical Center
Lebanon, New Hampshire
Grant/Research Support: National Institutes of Health, Bristol-Myers Squibb, Berlex Laboratories, Chiron Inc, Schering-Plough Corporation, Pfizer Inc; Consultant: Chiron Inc; Speakers' Bureaus: Berlex Laboratories, Chiron Inc, Schering-Plough Corporation, Pfizer Inc

Keith Flaherty, MD

Assistant Professor of Medicine
University of Pennsylvania Medical Center
Philadelphia, Pennsylvania
Consultant/Advisory Board: Bayer Pharmaceuticals, Onyx Pharmaceuticals, Plexikon, Chiron, AstraZeneca, Schering-Plough, Genentech

Lawrence E. Flaherty, MD*

Professor of Medicine and Oncology
Karmanos Cancer Institute
Wayne State University
Detroit, Michigan
Grants/Research Support: Schering-Plough Corporation, Chiron Therapeutics, Celgene, Bayer; Consultant: Bayer; Speakers' Bureaus: Schering-Plough Corporation, GlaxoSmithKline

James S. Goydos, MD, FACS*

Associate Professor of Surgical Oncology
Robert Wood Johnson Medical School
Cancer Institute of New Jersey
New Brunswick, New Jersey
Speakers' Bureau: Schering-Plough Corporation

James M. Grichnik, MD, PhD

Associate Professor
Duke University Medical Center
Durham, North Carolina
Founder and Major Shareholder: DigitalDerm, Inc; Consultant/Grants: Electro-Optical Systems Inc.

Caron M. Grin, MD

Clinical Professor of Dermatology
University of Connecticut Health Center
Farmington, Connecticut
Speakers' Bureau: Schering-Plough

James G. Jakowatz, MD

Director
Melanoma Center
Associate Professor of Surgery
University of California, Irvine Medical Center
Orange, California
No financial relationships to disclose

Mohammed Kashani-Sabet, MD*

Associate Professor of Dermatology
Director, Melanoma Center
UCSF Cancer Center
University of California San Francisco School of Medicine
San Francisco, California
Consultant and Speakers' Bureau: Schering-Plough Corporation

Douglas Kondziolka, MD, MSc, FRCS, FACS*

Vice-Chairman of Neurological Surgery
Professor of Radiation Oncology
University of Pittsburgh
Pittsburgh, Pennsylvania
Consultant: Elekta Instruments

David H. Lawson, MD*

Professor of Hematology/Oncology
Winship Cancer Institute
Atlanta, Georgia
Grants/Research Support, Consultant, and Speakers' Bureaus: Chiron Therapeutics, Schering-Plough Corporation, Berlex Laboratories

Sancy Leachman, MD, PhD

Associate Professor
Huntsman Cancer Institute
Department of Dermatology at the University of Utah Health Sciences Center
Salt Lake City, Utah
Speakers' Bureau: Myriad Genetic Laboratories

Patricia K. Long, MSN, FNP

Physician Extender/Nurse Practitioner
University of North Carolina
Chapel Hill, North Carolina
No financial relationships to disclose

Ashfaq A. Marghoob, MD, FAAD

Associate Professor of Dermatology
Memorial Sloan-Kettering Cancer Center
Hauppauge, New York
No financial relationships to disclose

R. Dirk Noyes, MD, FACS

Co-Director
Surgical Oncology
Multidisciplinary Melanoma Clinic
University of Utah
Huntsman Cancer Institute
Salt Lake City, Utah
Speakers' Bureau: Schering-Plough Corporation

Steven J. O'Day, MD

Chief of Research
Director of Melanoma Program
The Angeles Clinic and Research Institute
Los Angeles, California
Grants/Research Support: Berlex Laboratories, Chiron Therapeutics, Novartis, Schering-Plough; Consultant: Synta Pharmaceuticals

Thomas E. Olencki, DO*

Clinical Professor
Division of Hematology/Oncology
James Cancer Hospital and Solove Research Institute
Ohio State University
Columbus, Ohio
Speakers' Bureau: Schering-Plough Corporation

David W. Oilila, MD*

Associate Professor of Surgery
Director, Multidisciplinary Melanoma Program
University of North Carolina School of Medicine
Chapel Hill, North Carolina
No financial relationships to disclose

Victor G. Prieto, MD, PhD*

Professor of Pathology
University of Texas M.D. Anderson Cancer Center
Houston, Texas
No financial relationships to disclose

Douglas S. Reintgen, MD*

Director
Lakeland Regional Cancer Center
Lakeland, Florida
Speakers' Bureau: Schering Oncology

Krista M. Rubin, MS, RN, FNP-C

Nurse Practitioner
Center for Melanoma
Massachusetts General Hospital
Division of Hematology/Oncology
Boston, Massachusetts
Speakers' Bureau: Schering-Plough Corporation

Wolfram Samlowski, MD

Head
Section of Melanoma, Renal Cancer and Immunotherapy
Nevada Cancer Institute
Las Vegas, Nevada
Grants/Research Support: Pfizer Inc; Speakers' Bureaus: Pfizer Inc, Bayer, AOI, Sci Med; Stockholder: Amgen, Chiron, GlaxoSmithKline, Pfizer Inc

Vernon K. Sondak, MD

Chief
Division of Cutaneous Oncology
H. Lee Moffitt Cancer Center
Professor
Departments of Interdisciplinary Oncology and Surgery
University of South Florida College of Medicine
Tampa, Florida
Speakers' Bureaus: Schering Oncology Biotech, Pfizer Inc

Kenneth K. Tanabe, MD

Chief
Division of Surgical Oncology
Massachusetts General Hospital
Associate Professor of Surgery
Harvard Medical School
Boston, Massachusetts
Speakers' Bureau: Schering-Plough Corporation

Alan Valentine, MD*

Associate Professor of Medicine
University of Texas M.D. Anderson Cancer Center
Houston, Texas
No financial relationships to disclose

Robert W. Weber, MD

Associate Director
Northern California Melanoma Center
St Francis Memorial Hospital
San Francisco, California
No financial relationships to disclose

Richard L. White, Jr, MD, FACS

Clinical Associate Professor
Department of Surgery
Carolinas Medical Center
Blumenthal Cancer Center
Charlotte, North Carolina
Speakers' Bureaus: Schering Oncology, Chiron Therapeutics

*Indicates Melanoma Care Coalition faculty members who contributed to the generation of content for this newsletter.

BARRIERS-TO-CARE FOR PATIENTS WITH MELANOMA: SPECIAL CARE ISSUES—PREGNANCY AND PEOPLE OF COLOR

By Ashfaq Marghoob, MD, FAAD, and Michael Bihari, MD

Pregnant women and people of color, especially African-Americans, represent a special challenge for dermatologists. Although these groups are a relatively small minority of patients with melanoma who present for care in dermatologists' offices, they have unique clinical attributes that require treating physicians to have an expanded scope of knowledge.

Because of their in-depth training, dermatologists play a critical role in the prevention, diagnosis, treatment, and management of melanoma. Dermatologists are increasingly assuming complete care for patients with primary melanomas, including the wide local excision of lesions, long-term surveillance for disease recurrence, and ongoing detection of new primary lesions.¹ These services are especially important for special-care populations.

Incidence of Melanoma in Pregnancy

The incidence of cancer during pregnancy is about 1 in 1000, and the types of malignancies diagnosed during pregnancy reflect those seen in nonpregnant women of the same age, with breast cancer, cervical cancer, and melanoma as the three most common forms.² Leachman et al, noting the changing demographics of pregnancy and the increasing incidence of melanoma in the general population, state that, "the rate of melanoma during pregnancy is likely to increase."²

Such data mean dermatologists will increasingly need to counsel and provide care for pregnant women with a diagnosis of melanoma, women who would like to become pregnant following treatment for melanoma, and women treated for melanoma who would like to use

hormonal-based contraceptives to prevent further pregnancies.

Outcome of Melanoma in Pregnancy

In an editorial in *Cancer*, Schwartz et al noted that a number of well controlled studies "have provided strong evidence that the clinical course, prognosis, and overall survival of pregnant women with melanoma (AJCC Stage I-II) is similar to that in nonpregnant women."³

In a large retrospective cohort study of 185 Swedish pregnant women with melanoma, Lens et al reported no difference in the overall survival of pregnant women with melanoma compared with nonpregnant women with melanoma. In addition, the authors found no evidence that pregnancy following a diagnosis of melanoma

(continued on page 21)

BARRIERS-TO-CARE FOR PATIENTS WITH MELANOMA: LACK OF COORDINATED MANAGEMENT OF BRAIN METASTASES

*By Ashfaq Marghoob, MD, FAAD, Thomas E. Olencki, DO,
Douglas S. Reintgen, MD, and Michael Bihari, MD*

After lung and breast cancer, melanoma is the third most common malignancy causing metastases to the brain and accounts for 20% to 54% of recognized deaths from melanoma.¹ In a retrospective review of 6953 patients with melanoma, Sampson et al² noted that the median survival time of the 702 patients in their series with doc-

umented brain metastases was 113.2 days, and these lesions contributed to the death of up to 95% of the patients in this group.

Treatment Methods

Treatment for melanoma brain metastases, which has wide variations around the country, is aimed at symptom relief and palliation. Majer

and Samlowski³ note that overall, apart from the exceptional patient who has a successful surgical resection of a brain lesion, current treatment strategies for melanoma brain metastases do not seem adequate and result in poor outcomes (median survival, 2–4 months).

When referring patients for the
(continued on page 22)

INTRODUCTION

Evidence-based guidelines such as those published by the National Comprehensive Cancer Network (NCCN) provide important staging and treatment information for practitioners involved in melanoma care. However, as with any disease, there is no one-size-fits-all answer to the management of melanoma. Diagnostic and therapeutic strategies are often dictated by special

circumstances related to patient or tumor characteristics.

This publication presents 4 cases involving melanoma in special circumstances: melanoma during pregnancy, in-transit melanoma, melanoma with an unknown primary, and head and neck melanoma. For each case, appropriate staging and therapeutic options are discussed; some of the topics covered include sentinel lymph

node (SLN) mapping and biopsy, surgical treatment, adjuvant therapy options such as interferon (IFN) alfa-2b and radiotherapy, regional therapies including isolated limb perfusion (ILP), and systemic treatments such as interleukin 2 (IL-2). The unique dilemmas posed by each case are addressed, and faculty recommendations are accompanied by analyses of published findings pertinent to these issues.

CASE 1

MALIGNANT MELANOMA AND PREGNANCY

By Clara Curiel-Lewandrowski, MD

CASE PRESENTATION

A 32-year-old woman presents at 28 weeks gestation with a “changing mole” on her back (Figure 1). The patient has a history of a high number of nevi and multiple skin biopsies. The lesion is clinically identified as “atypical” by the obstetrician and the patient is immediately referred for a skin biopsy. Histological evaluation confirms the diagnoses of superficial spreading malignant melanoma arising in the context of a dysplastic nevus. The tumor extends to 1.1-mm thickness, Clark level IV, without evidence of ulceration. The mitotic rate is 0 and there is no evidence of regression or other adverse prognostic indicators.

What would you recommend for this patient? (You may choose more than one.)

1. Wide local excision with a 1- to 2-cm margin
2. SLN biopsy with radioactive colloid alone
3. SLN biopsy with radioactive colloid and blue dye

4. Postpone wide local excision and SLN biopsy until normal delivery of the child has occurred

The faculty recommends that the patient undergo wide local excision AND SLN biopsy with radioactive colloid alone. On the basis of the initial evaluation, the patient’s melanoma is stage IB, T2a (thickness between 1.01 and 2 mm without ulceration).¹ Wide local excision with margins of 1 to 2 cm is the standard of care for primary cutaneous melanoma of this thickness, and NCCN clinical practice guidelines for melanoma also strongly encourage lymphatic mapping with SLN biopsy.² Lymph node involvement has been identified as the most important prognostic factor for patients with early melanoma.^{1,3}

Figure 1. A “changing mole” on the back of a 32-year-old pregnant woman.

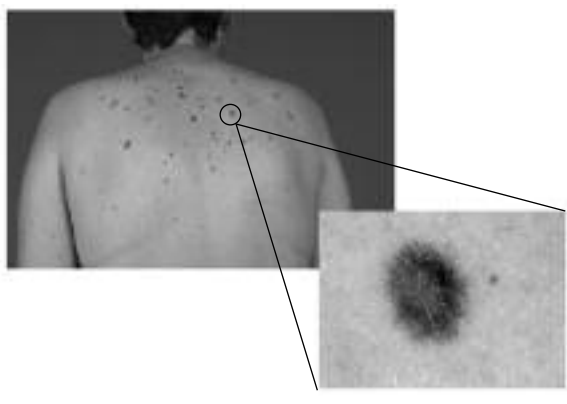


Image courtesy of Clara Curiel-Lewandrowski, MD.

Accordingly, SLN biopsy may play an important role in guiding therapy. Clinical experience indicates that pregnancy is not a contraindication to SLN. In a recent report of 9 women who underwent SLN biopsy during pregnancy for melanoma (n = 6) or breast cancer (n = 3), no adverse reactions to SLN biopsy were observed and all patients delivered healthy babies at term.⁴

The combination of a radioactive

colloid and blue dye is typically used to achieve SLN localization, as both agents together are more successful in mapping lymph nodes than either agent alone.⁵ However, the difference is small, and radioisotopes alone have a 92% to 98% success rate.^{5,6} Isosulfan blue is associated with allergic reactions in approximately 1% to 2% of patients, in some cases resulting in anaphylaxis and life-threatening complications.^{7,8} The faculty therefore recommends that this agent be avoided in pregnant patients. Radioactive colloids deliver whole fetal doses of <5 mGy during lymphatic mapping; one recent study of nonpregnant women with breast cancer projected a dose of 0.014 mGy to a hypothetical fetus.⁹ This level is well below the dose of 50 mGy considered safe during gestation by the Centers for Disease Control and Prevention.¹⁰ On the basis of these data, lymphatic mapping with radioactive colloids is not contraindicated in pregnant patients and carries a negligible risk.

Melanoma and Pregnancy

The risk of developing melanoma appears to be similar in pregnant and nonpregnant women. A population-based study conducted in California found that 8.5 pregnant women per 100,000 were diagnosed with melanoma from 1991 to 1999, within the range reported by the National Cancer Institute (melanoma incidence of 6.0 to 21.2 per 100,000 for women aged 20 to 45 years).¹¹ In one retrospective study, researchers found that higher parity (≥ 5 live births vs 0 live births) was associated with a reduced risk of melanoma, particularly in women who had their first child before 20 years of age.¹² However, Lea and colleagues reached the opposite conclusion in their case-control study, reporting that the risk of melanoma increased with an increasing number of live births.¹³ This issue currently remains unresolved.

Although there have been some

reports that melanocytic nevi change in color or size during pregnancy, particularly in women with dysplastic nevus syndrome,¹⁴ other studies have found that pregnancy is not associated with characteristic changes in nevi.^{15,16} Any changes in melanocytic nevi during pregnancy should be viewed with the same suspicion and assessed by the same criteria used in nonpregnant patients.

An important area of controversy is whether pregnancy alters the characteristics of melanoma, including the depth/thickness of the lesion, disease stage, and likelihood of metastasis. Some studies have reported that melanoma characteristics are similar in pregnant and nonpregnant women,¹¹ but others have found that tumors are thicker in pregnant women.^{17,18} The studies generally agree that pregnancy does not have an adverse effect on survival (reviewed by Leachman et al, 2007).¹⁹ As in the general population, prognosis of stage I/II melanoma in pregnant women is primarily dependent on tumor thickness and ulceration.¹⁸ A diagnosis of melanoma before or during pregnancy does not generally appear to negatively affect birth outcomes.²⁰ However, stillbirths were more prevalent in women diagnosed with melanoma within 2 years from the time of delivery (OR 4.6; 95% CI, 1.7-12.0, based on 5 stillbirths [1.4%] among 351 women).²⁰ Another potential rare complication relates to the increased rate of placental metastasis observed in melanoma cases when compared to other cancers. In patients with placental metastasis, there is a 22% chance that the fetus is also involved. Accordingly, the placentas of women with melanoma should be examined closely following delivery.²⁴

CASE CONTINUED

Wide local excision and SLN biopsy with radioactive colloid are performed. A total of 3 SLNs are excised, 2 from the right axilla and 1 from the left axilla. One of the nodes

from the right axilla is positive for metastatic disease by hematoxylin/eosin staining and immunohistochemistry. There is no evidence of extracapsular involvement.

What is your recommendation for a therapeutic procedure?

1. Perform a complete right axillary lymph node dissection without further delay
2. Postpone lymph node dissection until normal delivery of the child has occurred
3. Watchful waiting

The faculty recommends that a complete right axillary lymph node dissection be performed as soon as possible in consultation with the patient's obstetrician. The presence of a positive node changes the patient's staging to stage IIIA; the nodal status is N1a, indicating involvement of only a single node and no clinically palpable disease or gross extracapsular extension.¹ The NCCN recommends lymph node dissection or a clinical trial for all patients with stage III melanoma and N1a nodal status.² Although lymph node dissection is their general recommendation, the faculty notes that each case needs to be evaluated independently in consultation with the patient and an obstetrician. Relevant factors to consider include known comorbidities, age, and number of prior pregnancies. Fetal monitoring may be appropriate before and after maternal surgical procedure; guidelines published by the American College of Obstetricians and Gynecologists suggest that fetal monitoring should be individualized based on gestational age and type of surgery.²⁵

Case Continued: Adjuvant Therapy in Pregnancy?

A complete right axillary lymph node dissection is performed at 30 weeks' gestation without complications. Histologic evaluation reveals no evidence of additional metastatic disease (0 of 15 nodes).

What is your recommendation for adjuvant therapy? (You may choose

more than one.)

1. Initiate adjuvant therapy with IFN alfa-2b immediately
2. Postpone adjuvant IFN alfa-2b therapy until normal delivery of the child has occurred
3. Watchful waiting

The faculty recommends that IFN alfa-2b therapy be postponed until after delivery of the child, and that the patient's health be monitored with watchful waiting during this time. There are no adequate studies of IFN alfa-2b in pregnant women at the doses used for melanoma therapy. In rhesus monkeys, IFN alfa-2b has been found to have abortifacient effects. The US Food and Drug Administration (FDA) has classified IFN alfa-2b as pregnancy category C (adverse effects observed in animal reproduction studies, but no adequate studies in humans; benefit may outweigh risk for some patients).²⁶

Pregnancy After Melanoma

There are no standard defined guidelines for patients who wish to become pregnant after a diagnosis of melanoma. Recommendations regarding the length of time to wait after a diag-

nosis vary depending on the case and the physician. The main factors to consider when making specific recommendations include risk of recurrence (tumor thickness, stage), age of the patient, and the patient's desire to become pregnant.²⁷

Oral Contraceptives and Hormone Replacement Therapy

Data from the Nurses' Health Study suggested that current oral contraceptive use is associated with an increased risk of melanoma.²⁸ However, the most comprehensive assessment of data on this topic does not support this finding.²⁹ According to pooled analysis of 10 case-control studies, including 2391 cases and 3199 controls, oral contraceptive use is not associated with an increased risk of melanoma, and there is no association between melanoma incidence and current use of oral contraceptives, duration of contraceptive use, age of first use, sociodemographic characteristics, or any other factor or combination of factors that the investigators assessed.²⁹ A recent case-control study involving 318 white women also failed to detect a

link between melanoma and oral contraceptive use.¹³ In addition, there was no association between melanoma risk and the use of hormone replacement therapy.

CONCLUSION

Melanoma in pregnant women remains a controversial area in need of further study. As of yet, there is no clear evidence of pregnancy-associated differences in melanoma risk, presentation, or prognosis compared with patients who are not pregnant. However, the prevalent belief that pregnancy causes changes in nevi may lead patients or health care professionals to ignore potentially serious developments, resulting in late diagnosis. Systemic therapies for melanoma carry risk to the fetus, but diagnostic protocols such as SLN biopsy are relatively safe. Changes to nevi in pregnant women should be regarded with the same suspicion as in women who are not pregnant, and diagnosis and staging should be performed according to the stage of the disease. However, systemic therapies may need to be postponed until after delivery.

CASE 2

CLINICAL MANAGEMENT OF IN-TRANSIT MELANOMA

By Merrick I. Ross, MD, FACS

CASE PRESENTATION

A 47-year-old man presents with a 2.2-cm, irregularly pigmented, nonulcerated lesion on the back of the leg above the ankle. During the office visit, a 0.4-cm nodular lesion is noted just 1 to 2 cm proximal to the obvious primary lesion. The patient is otherwise in good health. Skin biopsy confirms that both lesions are melanoma. The primary tumor has a thickness of 1.6 mm, is Clark level III, and has histologic

ulceration. The smaller lesion is histologically consistent with metastasis in the dermis and therefore represents an isolated focus of satellite/in-transit disease.

Would you recommend SLN biopsy for this patient?

1. No, the presence of an in-transit lesion already indicates regional disease
2. Yes

Because this patient presents with a single satellite/in-transit lesion that

is in close proximity to the primary, the faculty recommends that the patient undergo SLN biopsy as a component of the initial management strategy. The use of SLN biopsy in this clinical scenario is controversial, but experience demonstrates that in patients with limited and small volume satellite disease, SLN biopsy can provide accurate and valuable information concerning the histological status of the draining regional lymph node basin. The SLN

identification techniques used for treating primary tumors are applied, but the injections are performed around the metastatic lesion. SLN positivity rates of up to 35% have been reported in such situations. In-transit and satellite melanomas are signs of regional disease, but knowledge of nodal status is still important because it may affect prognosis and treatment decisions. Patients with in-transit/satellite metastases without metastatic nodes are categorized as N2c, clinical stage IIIB, whereas those with in-transit/satellite metastases and nodal involvement are upstaged to N3 and to pathologic stage IIIC.¹ Five-year survival rates for patients with stage IIIB melanoma are generally around 50%, while 5-year survival rates for those with stage IIIC melanoma drop below 30%. Because patients with both in-transit metastases and nodal metastases have worse outcomes than patients with either one alone, these patients may wish to consider a more aggressive course of therapy.

In-Transit Melanoma: Incidence, Characteristics, and Prognosis

In-transit melanoma is caused by the spread of metastases through the lymphatic system. Metastatic sites are usually found between the primary lesion and the lymph node basin and can be manifested as either visible cutaneous/dermal lesions or palpable subcutaneous deposits. In-transit metastases are distinct from true "local recurrences," which represent regrowth of residual primary disease in or near the primary excision scar.³⁰ The most recent American Joint Committee on Cancer (AJCC) staging system does not distinguish between in-transit metastases and satellite metastases, as both result from intralymphatic spread.¹

In-transit melanoma is diagnosed at the same time as the primary melanoma in only about 5% of patients.³¹ The more common clinical scenario includes the development of in-transit lesions, not infrequently multiple, at some time

Table 1. Therapeutic options for the management of in-transit melanoma.²

Local

- Surgical excision
- Intralesional injection (bacillus Calmette-Guérin, IL-2, or IFN alfa-2b)
- Carbon dioxide laser ablation

Regional/Systemic

- Hyperthermic perfusion with melphalan
- Clinical trial
- Radiation therapy
- Systemic treatment with dacarbazine, temozolomide, high-dose IL-2, or dacarbazine- or temozolomide-based combination chemotherapy/biochemotherapy

Adjuvant (if free of disease)

- IFN alfa-2b

during the follow-up period subsequent to the appropriate wide excision and evaluation of the regional lymph node basin. Follow-up studies of patients who have been treated for primary melanoma reveal that 2.5% to 6.3% of these patients develop in-transit melanoma as a first recurrence (reviewed by Ross, 2007).³⁰ About half of in-transit metastases occur in patients whose primary site is on a lower extremity. The trunk is the second most common site (29%), followed by upper extremity (14%) and head and neck (7%).³² In-transit lesions usually occur between the primary site and the regional lymph nodes; however, lesions may occasionally develop retrograde to the primary melanoma site or in the soft tissue beyond the proximal basin.³⁰

Risk factors for the development of in-transit disease include age above 50 years, increased Breslow depth, Clark level greater than 3, ulceration, a positive SLN, and the location of the primary tumor on the lower extremity.^{31,32} Contrary to earlier reports suggesting that SLN biopsy may increase the rate of in-transit metastases, presumably through increased dissemination of tumor emboli due to proximal obstruction of the lymphatic system, subsequent studies have found no evidence to support this premise. The occurrence of in-transit disease appears to be linked to tumor biology, including tumor thickness and presence of positive lymph nodes, rather than to prior surgical interventions such as

SLN biopsy or lymphadenectomy.³²⁻³⁴

CASE CONTINUED

Wide local excision of the primary site, a negative-margin excision of the in-transit nodule, and SLN biopsy are performed. A single metastatic node is identified in the inguinal basin and completion lymph node dissection (CLND) reveals an additional positive node, for a total of 2 positive nodes out of 14. No extracapsular extension is observed. Imaging studies are negative for signs of distant disease. The patient does not wish to enroll in a clinical trial. *What other therapeutic approaches would you recommend?*

1. IFN alfa-2b therapy
2. ILP
3. ILP followed by IFN alfa-2b

The faculty recommends that the patient receive adjuvant therapy with IFN alfa-2b.

Overview of Management of In-Transit Melanoma

NCCN guidelines for melanoma list a wide variety of options for local and systemic management of in-transit melanoma (Table 1).² Considerations that influence the management of in-transit melanoma include the number, distribution, and location of lesions, the aggressiveness of the disease, and patient comorbidities. Patients with a limited number of distinct in-transit nodules are good candidates for surgical excision or other forms of local management, whereas diffuse or widespread disease may

require regional or systemic therapy.

Local management

NCCN guidelines state that complete surgical excision to clear margins is the preferred option for in-transit lesions, if feasible.² Because in-transit lesions are typically discrete and clearly separate from the surrounding dermis, wide margins are usually not necessary and may contribute to morbidity.^{30,35} Instead, discrete nodules can be excised macroscopically with narrow margins. Histopathologic analyses should be used to confirm clear margins.

Local management options for more widespread disease include carbon dioxide laser ablation and intralesional injection with bacillus Calmette-Guérin (BCG), IL-2, or other agents. Carbon dioxide laser ablation is an effective palliative therapy with low morbidity.³⁶ Intralesional local injections with BCG, IL-2 (with or without topical imiquimod), IFN alfa-2b, or other chemotherapeutic or biologic agents may also help control disease.^{2,37-39} Electrochemotherapy, in which a chemotherapeutic agent is administered in combination with electric pulses, has shown some promise in the local management of melanoma lesions.⁴⁰ In the event of multiple lesions on the extremities, ILP or the more recently described isolated limb infusion (ILI, see below) is often the preferred option

Adjuvant therapy

High-dose IFN alfa-2b is currently the only FDA-approved adjuvant therapy for metastatic melanoma. This therapy, consisting of 20 MU/m² intravenously 5 times per week for 4 weeks followed by 10 MU/m² 3 times per week for 48 weeks, has been assessed in 3 Eastern Cooperative Oncology Group (ECOG) trials in patients with high-risk melanoma. All three of the trials found that adjuvant therapy with high-dose IFN alfa-2b significantly improved disease-free survival compared with observation

(ECOG 1684 and 1690)^{41,42} or GMK (antiganglioside) vaccine (ECOG 1694).⁴³ A statistically significant improvement in overall survival was observed in 2 of the trials (ECOG 1684 and 1694).^{41,43} Although data for patients with in-transit melanoma were not specifically reported, the poor prognosis associated with in-transit disease suggests that aggressive adjuvant therapy is appropriate for this patient. The general good health and young age of this patient make him a good candidate for IFN alfa-2b.

CASE CONTINUED

Histopathologic analysis of the excised lesion confirms clear margins. The patient receives induction and maintenance therapy with high-dose IFN alfa-2b. One year later the patient returns with multiple diffuse lesions covering his lower leg. Imaging studies again show no signs of distant metastasis. The patient declines participation in a clinical trial.

What therapeutic options would you recommend for this patient?

1. A second course of IFN alfa-2b
2. Systemic therapy with IL-2
3. ILP

4. Chemotherapy with dacarbazine

The faculty recommends ILP, as they believe this approach has the best chance of achieving regional disease control. A modification of this procedure, ILI, has also been employed in patients with metastatic melanoma (Sidebar 1). Systemic IL-2 therapy may be another option. Although an overall survival benefit has not been clearly demonstrated for high-dose IL-2,⁴⁷ 6% of patients with metastatic melanoma experience a durable complete response.^{48,49} This potential benefit must be balanced against the significant toxicities associated with IL-2 therapy.

Isolated Limb Perfusion

Rationale

In older studies in which limb amputation was used to manage advanced or recurrent melanoma, the procedure was curative in 15% to 35% of patients.⁵⁰ Amputations are seldom employed in oncology today because of their high morbidity, but these findings suggest that aggressive regional therapies can, in some cases, be sufficient to control malignant melanoma. Given the poor effectiveness of current systemic treatments for melanoma,⁵¹ regional therapy is

Sidebar 1

Isolated Limb Infusion: An Alternative Form of Regional Perfusion

Isolated limb infusion (ILI), sometimes referred to as minimally invasive isolated limb perfusion, was developed to provide a simpler means of attaining the benefits of ILP. This technique employs percutaneously inserted catheters and is less invasive and technically complex than ILP. A pneumatic tourniquet is used in conjunction with a low-flow, nonoxygenated perfusion circuit that is manually circulated with a syringe. The limb vasculature is perfused with chemotherapeutic agents for approximately 30 minutes and then flushed with crystalloid solution.^{30,44}

Although no randomized trials comparing ILI and ILP have been conducted, these two forms of regional treatment appear to achieve similar response rates and durations of response. An analysis of 135 patients treated with ILI for melanoma reported a complete response rate of 41% and an overall response rate of 85%.⁴⁵ The median duration of response was 16 months, while median patient survival was 34 months.

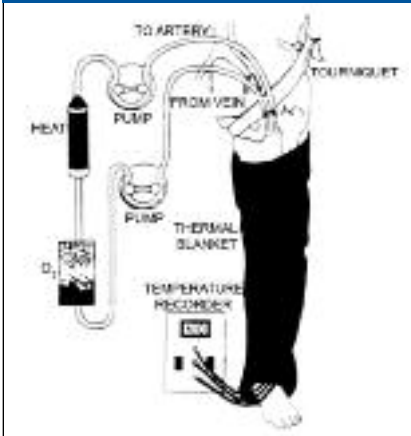
Regional toxicity with ILI is similar to that observed with ILP. In the study discussed above, grade I/II toxicity occurred in 42% of patients, grade III in 53%, and grade IV in 5%. Although CK levels are correlated with toxicity after ILP, this does not appear to hold true for ILI.⁷⁵ A recent study reported that hospital stays are longer after ILI (median 7 days) than after ILP (median 5 days), despite the less invasive nature of ILI. The increased hospital time following ILI was primarily due to monitoring for adverse events, as muscle injuries and CK elevations took longer to develop following this procedure.^{30,46}

an attractive option.

Regional perfusion therapy, in which high doses of cytotoxic drugs are delivered to a limb, has several potential advantages in the management of regional metastatic melanoma. This mode of therapy treats the entire limb at risk, including both cutaneous and subcutaneous lesions. In contrast, carbon dioxide lasers, surgical excision, and topical agents are confined to the treatment of cutaneous lesions and are not appropriate for widespread disease. Unlike systemic therapies, regional perfusion therapy is associated with high response rates and minimal systemic toxicity.

The location of the disease within the extremity is important to the success of regional perfusion. If some in-transit metastases occur high and lateral on the limb, outside the area to be perfused, then ILP is unlikely to be successful. Patients with evidence of distant metastases are generally not considered candidates for ILP, as systemic therapy is more likely to slow overall disease progression. However, patients with extensive involvement of a limb resulting in significant morbidity may benefit from ILP, even in the presence of distant disease.⁵² For these patients, perfusion may help control disease, reduce pain and

Figure 2. Schematic diagram of isolated limb perfusion technique, in which circulation to an extremity is controlled by ligating the collateral circulation and applying a tourniquet.



Courtesy of Merrick I. Ross, MD, FACS.

Figure 3. Typical response to hyperthermic limb perfusion with melphalan. A, pre-treatment extent of disease. B, postperfusion response; the only sign of disease remaining is pigmented macrophages in the dermis.

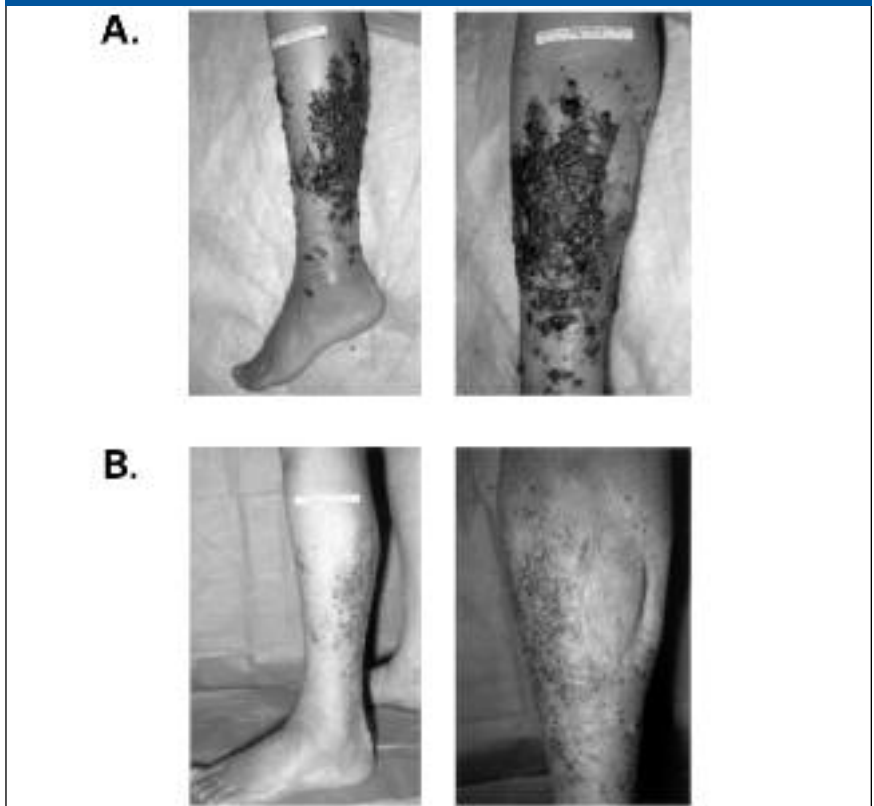


Image courtesy of Merrick I. Ross, MD, FACS.

symptoms, improve the quality of life, and allow administration of more aggressive systemic therapy.³⁰

Procedure

ILP is a surgical procedure in which circulation to an extremity is isolated from systemic circulation, and chemotherapeutic agents are then administered to the affected limb (Figure 2).³⁰ A key step in this procedure is the identification and surgical ligation of arterial and venous side branches. If the limb is not successfully isolated, drug concentrations in the limb may be reduced to ineffective levels, and systemic toxicity may occur. Isolation can be assessed by administering autologous radiolabelled blood cells into the bypass circuit and monitoring for leaks. The perfusate is typically heated to provide mildly hyperthermic conditions (39° to 40°C). Heat

improves response rates,⁵³ but temperatures above 40°C also result in a greater risk of severe toxicity.⁵⁴ Perfusion generally continues for 1 hour after the target temperature is reached, followed by a 30-minute washout period.^{30,35}

Outcomes

Melphalan is the agent most frequently used in ILP procedures. Other chemotherapeutic drugs, including nitrogen mustard, cisplatin, and dacarbazine, have resulted in lower response rates and are not commonly employed (reviewed by Fraker, 2004).⁵⁵ ILP with melphalan alone results in overall response rates of 65% to 99% and complete response rates of 41% to 73% (reviewed by Ross, 2007).³⁰ A typical response to ILP with melphalan is shown in Figure 3.

For patients experiencing an objec-

tive response to melphalan ILP, the median duration of response ranges from 5 to 14 months.⁵⁶ In a retrospective review of patients with melanoma treated at a single institution with hyperthermic melphalan ILP, 33 of 58 patients (57%) had a complete response.⁵⁷ Of these, 11 (33%) had a local recurrence, with a median time to recurrence of 13.4 months (range, 6.9 to 44.8 months). ILP has been reported to reduce the number of lesions and extend the recurrence-free interval within the limb by about 5 times in patients with frequently recurring in-transit metastases previously managed by surgery.⁵⁸ Recurrences can often be successfully managed by excisions for isolated lesions or repeat ILP for more widespread disease.^{59,60}

The impact of ILP on overall survival is harder to assess. It is notable, however, that a complete response to ILP has been identified as a strong predictor of survival in several studies.^{57,61,62} In one study, patients with a complete response were more than twice as likely to be alive at 3 years postperfusion when compared with patients who did not have a complete response (67% vs 28%).⁵⁷ Additional favorable prognostic features for patients undergoing ILP include lower disease stage, favorable primary lesion features (eg, thickness and Clark level), fewer lesions, in-transit lesion size of less than 1.4 cm², and absence of prior systemic therapy.^{61,63,64} Overall survival was not influenced by nodal status,⁶⁴ suggesting that regional perfusion remains a potentially effective therapeutic strategy in patients with positive lymph nodes.

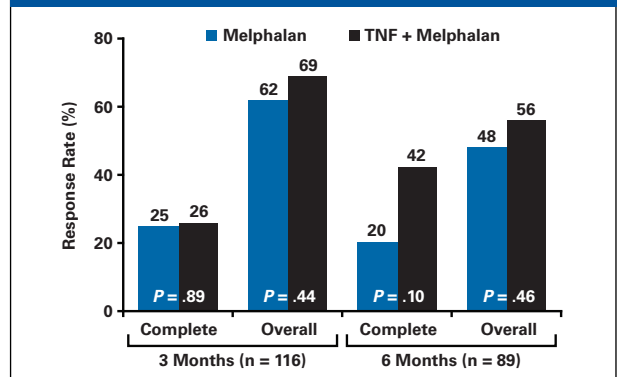
The addition of biologic agents, particularly tumor necrosis factor (TNF) and IFN gamma, to melphalan has been explored in the hope of improving the rate of complete response, durability of response, and survival. In 1992, Lienard and colleagues reported a 100% overall response rate and 91% complete response rate in 23 patients with melanoma who received ILP with

melphalan plus TNF and IFN gamma.⁶⁵ Overall survival at 1 year was 76% and disease-free survival was 70%. A literature review by Grünhagen and colleagues reported improved complete response rates (59% to 90%) for patients treated with melphalan plus TNF, sometimes in combination with

IFN gamma, compared with historical data from patients treated with melphalan alone (40% to 82%), but these studies were not randomized (reviewed by Grünhagen et al, 2006).⁵⁶

Data from randomized studies have been somewhat less encouraging. A phase 2 clinical trial found that the 3-agent combination of IFN gamma, melphalan, and TNF did not significantly improve response rates over the 2-agent combination of melphalan plus TNF, suggesting that the addition of IFN gamma had a negligible impact on outcomes.⁶⁶ More recent studies have also called the contribution of TNF into question. The American College of Surgeons Oncology Group (ACOSOG) Z0020 trial randomized patients with locally advanced extremity melanoma to hyperthermic ILP with melphalan alone or melphalan plus TNF.⁶⁷ The primary end point was tumor response at 3 months. The study was terminated early because of lack of evidence of a difference favoring the melphalan plus TNF arm. Assessments of available data for response to treatment at 3 months (n = 116) and 6 months (n = 89) revealed that response rates in both arms were much lower than had been reported in other trials. However, some patients continued to improve at 6 months, suggesting that the maximal response to melphalan plus TNF may not have been achieved by the 3-month primary end point (Figure 4). At 6 months,

Figure 4. Complete and overall response rates at 3 and 6 months in ACOSOG Z0020.⁶⁷



complete responses were observed in about twice as many patients in the melphalan plus TNF arm as in the melphalan monotherapy arm, but this difference did not reach statistical significance (P = .10). The authors suggested that procedural differences, TNF preparations, drug pharmacokinetics, or patient selection might explain the lower response rates observed in their study.⁶⁷ The ACOSOG Z0020 trial did not address survival rates. A retrospective analysis of patients treated with ILP using melphalan alone (n = 40) or melphalan plus TNF (n = 90) did not identify any significant differences in recurrence-free or overall survival.⁶¹

Safety

ILP can result in acute regional toxicity to the skin and tissue of the treated limb as well as systemic toxicity caused by the perfusate leaking into systemic circulation. Acute tissue reactions are graded on a 5-point scale developed by Wieberdink and colleagues, ranging from grade I (no reaction) to grade V (reaction that may require amputation; Table 2).⁶⁸ A retrospective review found no significant differences in acute toxicities associated with single-agent melphalan ILP and melphalan plus TNF ILP.⁶¹ Most patients experienced only a minimal reaction of slight edema, erythema, and pain, but 25% to 29% experienced more severe reactions (Table 2).

The major complications associated

with regional perfusion are wound infection (11% to 20% of patients) and venous thrombosis (approximately 2% of patients or fewer). Long-term morbidities include edema, neuropathy, muscle atrophy, and limb malfunction.⁶¹ Monitoring of creatinine kinase (CK) levels and frequent physical examinations may aid in the early detection of postperfusion muscle injury.^{30,69} One retrospective analysis found that at 1 year after perfusion, 44% of patients showed some morbidity, primarily lymphedema (which may also be due to lymph node dissection), muscle atrophy or fibrosis, or limb malfunction.⁷⁰ In a quality-of-life study of long-term survivors of melanoma treated with ILP, approximately half of the patients interviewed complained of problems with limb function.⁷¹ Nevertheless, the overall health-related quality of life of these patients was comparable to that of healthy individuals.

Systemic toxicities associated with melphalan include rashes, bone marrow depression, gastrointestinal symptoms, and hair loss. A retrospective study of patients receiving melphalan ILP between 1978 and 1990 found that 27% showed some form of systemic toxicity; the most common manifestation was nausea and vomiting.⁷² However, systemic toxicity was rarely severe.

High-dose TNF can cause significant systemic effects, including fever, chills, hypotension, and acute respiratory distress.⁷³ However, if limb isolation is effectively achieved, TNF-associated toxicity following ILP is generally mild, consisting mainly of fever and nausea/vomiting. Patients with higher TNF levels after ILP may also exhibit tachycardia or hepatotoxicity.⁷⁴

Perfusion as adjuvant therapy

Two randomized trials have examined regional perfusion as adjuvant therapy in patients with melanoma.^{75,76} Neither found ILP suitable for use in this context, but both studies had important limitations. The role of

Table 2. Acute regional toxicity associated with single-agent melphalan ILP (n = 40) and melphalan plus TNF ILP (n = 90) in patients treated in the Netherlands between 1978 and 2001.^{51,68}

Grade	Definition	Single-Agent Melphalan ILP (%)	Melphalan Plus TNF ILP (%)
Grade I/II	No reaction/slight erythema and/or edema	71%	75%
Grade III	Considerable erythema and/or edema with some blistering; slight disturbed motility permissible	26	23%
Grade IV	Extensive epidermolysis and/or obvious damage to the deep tissues, causing definite functional disturbances; threatening or manifest compartmental syndromes	3%	2%
Grade V	Reaction that may necessitate amputation	0%	0%

ILP as adjuvant therapy in carefully selected patients therefore remains an open question.

In the trial reported by Kooops and colleagues, patients with limb melanoma with a thickness of at least 1.5 mm and no clinical evidence of satellitosis, in-transit lesions, lymph node involvement, or distant metastases were randomized to treatment with either wide local excision alone (n = 412) or wide local excision plus ILP with melphalan and mild hyperthermia (n = 420).⁷⁵ There was a trend for longer disease-free survival with ILP after a median follow-up of 6.4 years and regional control was improved in the ILP group: the appearance of in-transit metastases was reduced from 6.6% to 3.3%, and metastases to regional lymph nodes were decreased from 16.7% to 12.6%. However, no impact was observed on overall survival or distant metastasis.⁷⁵ This may not be surprising, as the development of in-transit lesions occurred in only 6.6% of the non-ILP patient population, suggesting that the risk of in-transit disease in this population was not high enough to demonstrate an effect of regional perfusion therapy on survival.

A smaller study by Hafström and colleagues examined a higher-risk population, patients with local recurrences or in-transit metastases.⁷⁶

Patients with recurrent melanoma received either surgery alone (wide local excision plus lymph node dissection; n = 36) or surgery plus hyperthermic regional perfusion with melphalan (n = 33). Although regional perfusion significantly improved disease-free survival (median of 17 months vs 10 months for surgery alone; $P = .044$), the difference in overall survival was not significant (57 months vs 35 months; $P = .28$).⁷⁶ Because of its small size, however, this study was underpowered. A large-scale study of high-risk patients will be required to adequately address the impact of adjuvant ILP on recurrent melanoma of the limb and any potential impact on overall survival.

CONCLUSION

In-transit melanoma is caused by intralymphatic metastasis and can be difficult to treat. Patients with discrete lesions may benefit from excision with narrow margins or other forms of local management, whereas diffuse disease may require regional or systemic therapies. ILP or ILI with melphalan is associated with high response rates and limited systemic toxicity. The impact of regional perfusion as adjuvant therapy in patients at high risk for in-transit lesions has not yet been adequately studied.

**CASE
3**

MANAGEMENT OF METASTATIC MELANOMA WITH UNKNOWN PRIMARY SITE

By Mohammed Kashani-Sabet, MD, and Merrick I. Ross, MD, FACS

CASE PRESENTATION

A 54-year old man presents with a small right axillary mass. Fine needle aspiration biopsy is performed, and cytologic analysis indicates metastatic melanoma. A thorough physical examination fails to reveal a primary site. There is no other lymphadenopathy. Imaging studies do not reveal signs of distant disease.

Lymphadenectomy is performed on the right axillary nodes; 3 of the 16 nodes are positive for melanoma. The largest involved lymph node measures 2.8 cm. No extracapsular extension is noted. The patient does not wish to enter a clinical trial.

What would you recommend as the next step in the management of this patient?

1. Continue to search aggressively for the primary site
2. Treat the patient with adjuvant IFN alfa-2b
3. Treat the patient with IL-2
4. Treat the patient with radiotherapy and adjuvant IFN alfa-2b

The faculty recommends that the patient receive adjuvant IFN alfa-2b therapy. As discussed below, recent studies suggest that patients with melanoma of unknown primary origin (MUP) are generally more similar to patients with known primaries and stage III disease than to those with stage IV melanoma. These patients may therefore benefit from stage III adjuvant therapy protocols.⁷⁷ The combination of radiotherapy and IFN alfa-2b may also deserve consideration, as adjuvant radiotherapy improves regional control compared with historical data from patients managed using surgery alone (reviewed by Ballo and Ang, 2004).⁷⁸ The suggested indications for nodal irradiation are extracapsular

extension, 4 or more involved lymph nodes, lymph node 3 cm or larger, cervical lymph node location, or recurrent nodal disease.⁷⁸ Because this patient does not have any of these indications and because the combination of IFN alfa-2b and radiotherapy can result in severe radiation-induced toxicity,⁷⁹ the faculty recommends that adjuvant therapy be confined to IFN alfa-2b treatment alone.

MUP Presentation and Etiology

Approximately 2% to 6% of patients with melanoma are diagnosed with MUP.⁸⁰ Current diagnostic criteria for MUP include (1) clinical, histologic, and immunohistochemical confirmation of metastatic melanoma; (2) the absence of a previous cutaneous tumor; and (3) no evidence of a primary tumor at unusual sites, including urogenital, otolaryngologic, or ophthalmologic sites.⁷⁷ Components of an initial evaluation for MUP are shown in Table 3.

The median age of patients with

MUP is approximately 50 years, and this diagnosis is more common in men than in women.^{77,81} The most common site of metastasis for patients with MUP is the lymph nodes (65% of patients), followed by visceral lesions (28%) and subcutaneous nodules (8%).⁸¹ Axillary nodes are the most frequently involved lymph nodes, implicated in 54% to 76% of patients with lymphatic involvement. In a significant proportion of these patients (46% to 62%), only a single metastatic lymph node is identified.^{77,81}

Possible etiologies for MUP have been summarized by Anbari and colleagues.⁸¹ These include

- An antecedent, unrecognized, spontaneously regressed primary melanoma
- A previously excised, misdiagnosed primary site
- A concurrent, clinically unrecognized melanoma
- The metastatic site represents the primary lesion

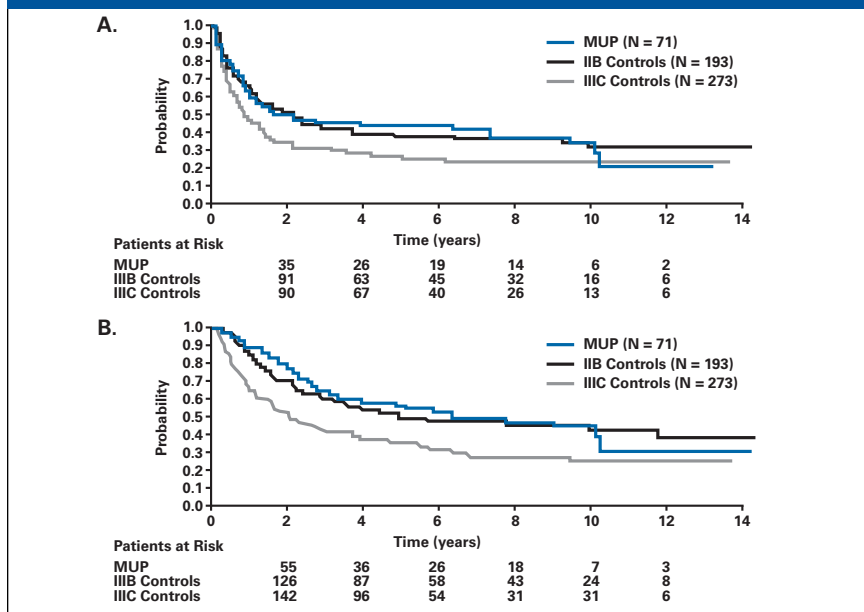
In one study, 20% of patients with

Table 3. Initial evaluation of a patient with MUP.

History	Prior atypical skin lesion that disappeared Prior biopsy of skin lesion not sent to pathology Atypical skin lesion locally destroyed Atypical skin lesion and biopsy benign
Physical	Careful skin and nodal exam Occult sites <ul style="list-style-type: none"> • Nose, conjunctiva, ear canal (cervical adenopathy) • Anorectum, vulva, genitalia, urethra (inguinal adenopathy) • Retina (liver metastases)
Imaging	Ultrasound other nodal basins PET/CT to determine: <ul style="list-style-type: none"> • Extent of disease • Accurate staging • Initial treatment
Pathology	Careful review (expert consultation) of submitted tissue Procurement and review of previous skin biopsy material

Courtesy of Merrick I. Ross, MD, FACS. CT indicates computed tomography; PET, positron-emission tomography.

Figure 5. Survival in patients with metastatic melanoma in lymph nodes arising from an unknown primary site (MUP) compared with a control group of patients who had known primaries and stage IIIB/IIIC disease. A, disease free survival. B, overall survival.⁷⁷



Reprinted with permission from Cormier JN, et al. *Cancer*, 2006.

MUP had a history of spontaneously regressed lesions, suggesting that the first of these proposed etiologies may account for a significant proportion of MUP cases.⁸¹

Prognosis

Most analyses of patients with MUP have been relatively small, and therefore outcome data have varied considerably. However, several studies have reported that the prognosis of patients with MUP is more favorable than the prognosis of patients with metastases from an identified primary.^{77,80,81} These reports raise the possibility that at least in some of these patients the index metastatic lesion is the primary and therefore manifest a prognosis more in line with advanced or neglected primary disease. Such a suggestion is not all that far-fetched, as capsular nevi in lymph nodes are not infrequently identified and the malignant transformation of these nevus cells could represent a primary tumor. Embryonic migration of neural crest cells and melanocytes to distant mucosal sites may explain the origin of the unusual clinical presentation of primary mucosal melanoma.

Migration to visceral mucosal/epithelial sites such as in lung (Sidebar 2) or esophagus and subsequent malignant transformation may explain some of the cases of single-site visceral metastases with unknown primary origin.

The most recent study of MUP assessed outcomes in 71 patients with involvement in a nodal basin compared with 466 control patients who had regional lymph node metastases with a known primary site.⁷⁷ The overall survival of patients with MUP was comparable to that of patients with regional (stage III) lymph node involvement (Figure 5) and far better than has historically been observed for patients with stage IV disease. Patients with metastasis to a single lymph node had similar outcomes regardless of whether they had an MUP or a known primary, and patients with N2b MUP (clinically apparent involvement of 2 to 3 lymph nodes) showed a nonsignificant separation of curves, but those with N3 MUP (4 or more lymph nodes or matted nodes) had better overall survival than patients with N3 melanoma and a known primary,

perhaps reflecting a more benign disease course for MUP. These findings suggest that patients with MUP and lymph node involvement should be treated in a manner appropriate for stage III disease, including the use of CLND and adjuvant therapy.⁷⁷

Case Study: An Alternative Scenario

The 54-year old male patient presents with a persistent, nonproductive cough. Chest x-rays detect a pulmonary nodule in the lower right lobe, and computed tomography scans suggest a malignant lesion. A transthoracic needle biopsy is performed and the nodule is found to be malignant melanoma. A primary site cannot be identified, and comprehensive imaging scans conducted at intervals over a 6-week observation period do not detect other signs of distant disease. The patient is otherwise in good health and refuses a clinical trial.

What treatment option would you recommend?

1. Systemic IL-2 therapy
2. Surgical resection
3. Continued observation

The faculty recommends surgical resection followed by observation. If the patient wishes to pursue a more aggressive treatment course, surgical resection may be followed by adjuvant IFN alpha-2b therapy or a clinical trial.² As discussed below, resection of isolated melanoma in the lung in the case of MUP results in particularly good outcomes. If multiple unresectable pulmonary lesions or lesions in more than one organ were detected, systemic therapy would be the preferred option.

Pulmonary Resection for MUP

The presentation of a patient with pulmonary melanoma in the absence of a known primary poses a diagnostic dilemma for physicians (Sidebar 2). There have been rare reports of primary pulmonary melanoma, possibly due to the aberrant migration of melanocytes to the lung and subsequent malignant transformation to a

Sidebar 2

Primary Pulmonary Melanoma or MUP?

Pulmonary melanoma metastases are fairly common, but primary pulmonary melanoma is quite rare. To date, fewer than 50 cases have been reported in the literature.⁸² Nevertheless, the presence of a single pulmonary lesion raises the possibility of primary pulmonary melanoma, as solitary lung metastases are observed in fewer than 1% of patients with melanoma.⁸³ Although melanocytes are not normally found in the lower respiratory tract, primary pulmonary melanoma may arise from residual primitive melanoblasts in the lung.⁸⁴

The following clinical criteria have been proposed to aid in the diagnosis of primary pulmonary melanoma (reviewed by de Wilt et al, 2005)⁸⁵:

- No previously removed pigmented skin lesions or ocular tumors
- No demonstrable melanomas in other organs at the time of surgery
- Only a solitary tumor in the surgical specimen
- Morphologic features compatible with a primary tumor
- No primary malignant melanomas at autopsy (if available)

Histologic criteria have also been devised to help distinguish pulmonary primary melanomas from pulmonary MUP, but these have proven to be less useful than clinical characteristics.⁸⁵

In a review of the literature, long-term survival was achieved by approximately 33% of patients with primary pulmonary melanoma treated by resection.⁸⁶ These data suggest that management strategies should be similar for patients with a solitary pulmonary lesion, regardless whether the melanoma represents a primary site or metastasis from an unknown primary.

primary tumor. The other alternative is that the pulmonary melanoma represents metastasis from an unknown primary.⁸² The lung is second only to skin as the most common first site of distant metastases; in one study, 36% of patients with distant melanoma metastases had a pulmonary metastasis.⁸⁵ Regardless whether the pulmonary lesion represents primary melanoma or a metastasis, however, management options remain the same. For patients who do not have

significant comorbid conditions, surgical resection is usually considered to be the best therapeutic strategy for limited pulmonary disease.⁸²

Pulmonary metastasectomy is a significant predictor of improved survival in patients with metastatic melanoma.⁸⁷⁻⁸⁹ In a retrospective review of patients with pulmonary melanoma metastases, the outcomes in 106 patients who underwent resection were compared with those in 878 patients who did not. Surgical patients had survival rates of 77% at 1 year, 37% at 3 years, and 27% at 5 years, compared with 32%, 7%, and 3%, respectively, for nonsurgical patients.⁸⁹ Subsequent resection for limited recurrence in the lung is also associated with a survival advantage compared with systemic therapies ($P < .0001$).⁹⁰ These figures are probably aided by a selection bias in which healthier patients are more likely to be chosen for surgery. Nevertheless, the dramatic effect of metastasectomy on survival suggests that this procedure may have at least some therapeutic benefit. The best outcomes are observed in patients with a solitary lesion. Andrews and colleagues reported a median survival time of 41 months in patients with 1 lesion, compared with 25 months for those with more than 1 lesion ($P = .05$).⁹⁰

Ollila and colleagues performed an analysis of prognostic indicators in 45 patients with melanoma who were treated by pulmonary resection.⁹¹ The only factors that predicted survival in this study were tumor doubling time and the type of pulmonary resection (curative vs palliative). Patients with a tumor doubling time of less than 60 days had a median survival time of 16 months and a 0% 5-year survival rate, while those with a doubling time of 60 days or more had a median survival time of 29.2 months and a 20.7% 5-year survival rate.⁹¹ The determination of tumor doubling time prior to surgery may provide important prognostic information and help guide adjuvant therapy choices.

de Wilt and colleagues evaluated outcomes in 15 patients who

presented with pulmonary MUP and were managed by surgical resection at the Sydney Melanoma Unit.⁸² Median disease-free survival following resection was 17 months (range 0 to 85 months), and median overall survival was 32 months (range 6 to 132 months). The 5-year survival rate was 42%, and 4 patients (26.7%) remained alive with no evidence of disease at a median of 74 months after resection. The outcomes reported in this analysis compared favorably to the 19-month median overall survival and 22% 5-year survival rate for all melanoma patients treated with lung resection at the Sydney Melanoma Unit.⁸² These data suggest that pulmonary resection is at least as successful in patients with MUP as in patients with known primary sites, and resection should be the option of choice for patients with resectable lesions who are healthy enough for surgery.

CONCLUSION

The clinical entity of MUP represents a heterogeneous spectrum of disease with nodal involvement the most common presentation, but other soft tissue disease and isolated visceral metastases account for a significant percentage of the patients. While the studies in MUP are limited by the small populations involved, some recent data indicate that MUP is associated with a history of spontaneously regressed lesions and an improved prognosis relative to patients with a known primary and metastases. The bulk of the literature however, suggests that the survival of MUP patients with nodal disease is essentially similar to that of AJCC stage III patients, supporting an aggressive surgical approach including CLND and systemic adjuvant therapy. For MUP patients presenting with isolated visceral disease surgical resection should be strongly considered, particularly in those patients with pulmonary lesions, as this may represent a similar biology as other patients with isolated stage IV disease or the actual primary site.

CASE 4

THERAPEUTIC OPTIONS FOR HEAD AND NECK MELANOMA

By David W. Ollila, MD

CASE PRESENTATION

A 49-year-old man presents with a large, heterogeneous, pigmented lesion just to the left of the vertex of the scalp. It measures 1.8 cm by 1.3 cm. Punch biopsy is performed in two different locations, and both reveal desmoplastic melanoma (DM), Clark level IV, Breslow thickness 1.9 mm. Histopathologic evaluation indicates mixed DM; approximately 40% of the tumor has non-desmoplastic features.

What is your first step in the treatment of this patient?

1. Wide excision
2. Wide excision and SLN biopsy
3. Wide excision and elective lymph node dissection

The faculty strongly recommends that wide excision and SLN biopsy be performed. This patient is currently clinical stage IB, T2a (primary tumor 1.01-mm to 2.0-mm thick without ulceration).¹ During excision, careful attention should be paid to ensuring adequate surgical

margins, as approximately 20% of patients with DM require re-excision because of positive margins.⁸⁴

Approximately 5% of patients who present with head and neck melanoma and 8% of those with DM have nodal involvement,^{84,92} but this figure is much higher (16% to 18%) in patients with mixed DM.^{93,94} Lymph node status is the most important prognostic factor for survival in patients with cutaneous melanoma.³ As discussed below, lymphoscintigraphy studies have shown that the location and number of SLNs in patients with head and neck melanoma cannot be accurately predicted based on expected lymphatic drainage patterns.⁹⁵⁻⁹⁷ Accordingly, SLN mapping and biopsy is a critical step in treating head and neck melanoma.

Overview of Head and Neck Melanoma

Head and neck melanoma accounts for 10% to 20% of cutaneous melanoma cases,⁹⁸ perhaps because of

the increased sun exposure of these areas. About half of patients with head and neck melanoma have lesions on the face; other common sites include the neck, scalp, and ear. Rare cases on the eyelids and lips have also been reported.^{98,99}

The proportions of the histologic melanoma subtypes associated with head and neck melanoma are shown in Figure 6. Of the various histologic subtypes, nodular melanoma is associated with the worst prognosis.⁹⁸ Prognostic features for patients with head and neck melanoma are similar to those in patients with melanoma at other sites and include tumor thickness, ulceration, and Clark level.⁹⁸

Desmoplastic Melanoma

Although DM is an uncommon subtype, accounting for only 3% to 4% of cutaneous melanoma cases,⁸⁴ about half of DM lesions occur on the head and neck.¹⁰⁰ DM has a variable presentation and may appear as a pigmented lesion or a nonpigmented papule,

Figure 6. Percent of each histological subtype in a study of patients with cutaneous head and neck melanoma (n = 2218).⁹⁸

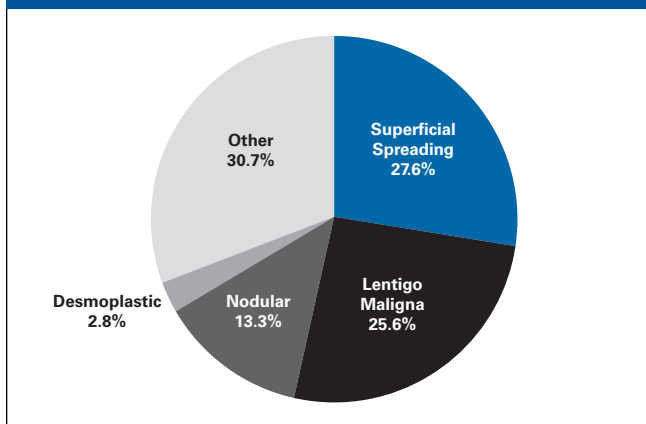
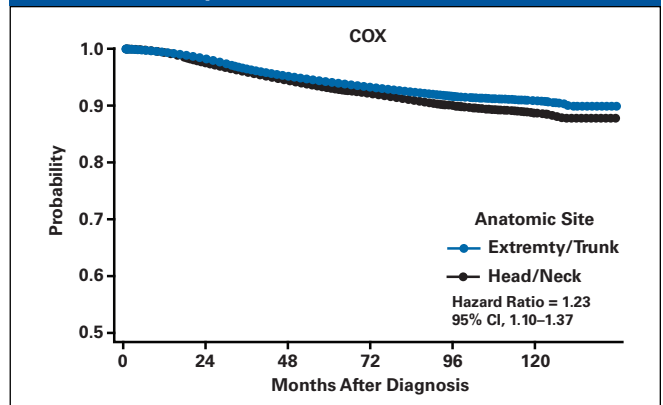


Figure 7. Predicted melanoma-specific survival curves of patients in the SEER database based on a Cox model adjusted for age, sex, thickness, ulceration, lymph node status, and UV exposure.



Courtesy of A. M. Lachiewicz, MD.

plaque, or nodule.¹⁰⁰ About 44% of DM lesions are amelanotic.¹⁰¹ In its early stages, DM may be missed or misdiagnosed because of its atypical appearance. DM can occur with or without neurotropism¹⁰⁰ and is classified as “pure” (prominent fibrosis throughout the entire tumor) or “mixed” (only part of the melanoma exhibits desmoplastic features) on the basis of histopathology.^{93,94}

DM typically appears in an older patient population (median age 65 years) than other forms of melanoma (median age 53 years).⁹³ A meta-analysis of 17 studies of patients with DM reported that DM is more common in men than in women (1.7:1).¹⁰⁰ Mean Breslow thickness at presentation ranged from 2.0 to 6.5 mm in this analysis, and the majority of tumors were Clark level IV (48% to 74%) or V (23% to 48%). In a retrospective analysis of 129 patients with DM in the Duke Melanoma database, 22% of primary tumors were ulcerated and neurotropism was present in 75%.¹⁰² Only 6% of patients had evidence of lymph node involvement (stage III) at presentation; the remainder of patients presented with primarily stage I (29%) or stage II (65%) disease.¹⁰² The meta-analysis described earlier found local recurrence to be more common (27%) than regional (7%) or systemic (20%) recurrence.¹⁰⁰

The clinical presentation and prognosis of DM vary depending on whether it is histologically pure or mixed.^{93,94} In a study by Pawlik and colleagues, pure DM tumors were thicker, more invasive (Clark level V), and less likely to be ulcerated than mixed or non-DM tumors. Pure DM was also associated with lower rates of nodal involvement (2%, compared with 16% for mixed DM and 18% for non-DM [$P < .01$]) and recurrence (0, compared with 21% for mixed DM and 16% for non-DM at a median follow-up of 2.9 years [$P = .002$ vs non-DM]).⁹⁴

The thickness of DM at presentation is typically greater than that for other subtypes of melanoma, and

this fact can skew survival analyses. To circumvent this problem, Livestro and colleagues conducted a case-control comparison in which patients were matched for tumor thickness, age, sex, and year of diagnosis.⁸⁴ Patients with DM were less likely to present with stage III or IV disease (5% vs 21%), less likely to have a positive nodal status (8% vs 34%), and more likely to require re-excision to obtain clear surgical margins (21% vs 6%) than patients with other forms of melanoma. Despite these differences, the DM and non-DM groups showed similar rates of 5-year overall (72.6% vs 76.9%) and disease-free survival (65.7% and 67.4%).⁸⁴ Predictors of survival in patients with DM include mitotic rate, tumor thickness, patient age, and disease stage at presentation.^{84,101,102}

Impact of Anatomic Site on Prognosis

Although head and neck melanomas share many characteristics with melanomas found at other anatomic sites, some evidence suggests that they may have a different biology and prognosis. However, the literature on this point varies widely.¹⁰³⁻¹⁰⁶ A recent study of patients with head and neck melanoma suggested that there may even be important differences in prognosis depending on the exact site of melanoma within the head and neck region, with significantly increased risk of mortality in patients with scalp or neck melanomas compared with melanomas on the facial region.¹⁰⁷

A study of 129 patients with DM revealed a trend toward poorer 5-year survival rates for patients with head and neck DM (67%) than for patients with other primary site locations (85%), but this difference did not achieve statistical significance ($P = .71$), perhaps because of the small number of patients involved.¹⁰²

Lachiewicz and colleagues used the Surveillance, Epidemiology, and End Results (SEER) database to examine the epidemiology of melanoma.¹⁰⁸

Ten-year survival rates were 83.8% for patients with head and neck melanoma ($n = 9490$) compared with 86.7% for patients with melanoma at other sites ($n = 42,214$; $P = .0003$).⁹² After adjusting for sex, age, thickness, ulceration, and lymph node involvement, patients with head and neck melanoma were found to have a 1.23-fold increase in mortality rate compared with other melanoma patients (Figure 7). Although this difference is fairly modest, the size of the study lends weight to its conclusion.

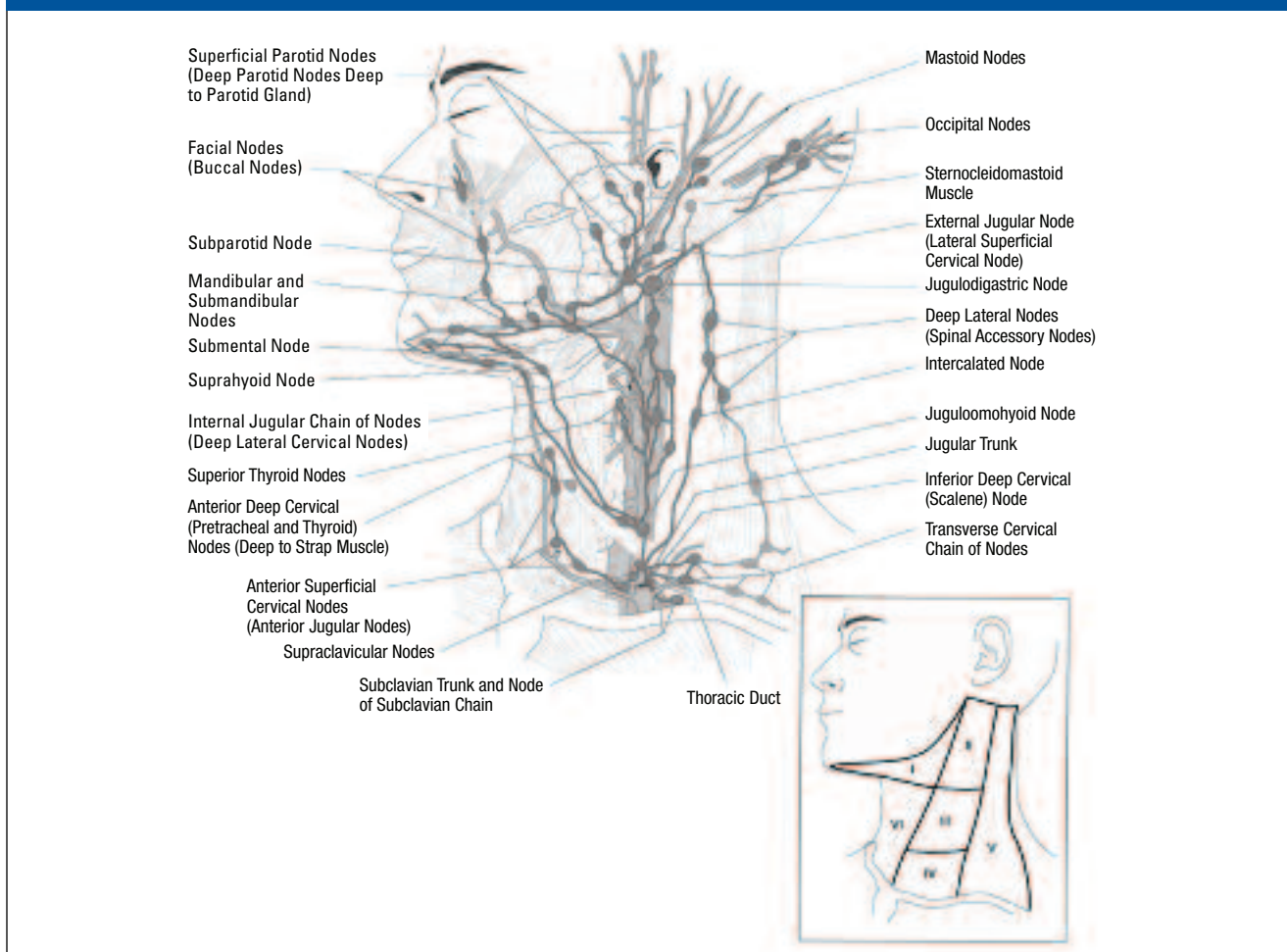
SLN Mapping and Biopsy in Patients With Head and Neck Melanoma

Lymphatic drainage from the head and neck area is extremely complex, involving multiple node fields (Figure 8).^{109,110} It is virtually impossible to accurately predict which lymph nodes may be involved; studies of patients with head and neck melanoma have found that lymphoscintigrams do not agree with clinical predictions in 25% to 43% of cases.⁹⁵⁻⁹⁷ One retrospective analysis found metastatic lymph nodes in discordant sites in 13.7% of node-positive patients with head and neck melanoma, indicating that discordant nodes can be clinically significant and warrant biopsy.⁹⁵

SLN biopsy is more technically challenging in patients with head and neck melanoma than in patients with melanoma at other sites. Most patients with head and neck melanoma have multiple SLNs, either in different basins or in the same basin. The mean number of SLNs per patient is approximately 2.5 to 2.75.^{95,96} It can be easy to miss SLNs that lie underneath the primary tumor or are very small.⁹⁵ Despite these difficulties, it is critical that all SLNs be removed and analyzed, including those seen on lymphoscintigram, those identified by handheld Geiger counters, and blue-stained or palpable nodes.

In experienced surgical hands, SLN biopsy of the cervical and parotid nodal basins is associated

Figure 8. Cervical lymph nodes that may be involved in lymphatic drainage from the head and neck region.



Reprinted with permission from Roseman BJ, Clark OH. Neck mass. In: Souba WW, Fink MJ, Jurkovich GJ, et al. *ACS Surgery: Principles & Practice*. Head and neck section. New York, NY: WebMD Inc.; 2004.¹⁰

with very low morbidity (3% to 4%), mostly consisting of temporary nerve paresis and seromas at the SLN biopsy site.^{111,112} In fact, an assessment of complications associated with SLN biopsy in patients enrolled in the Sunbelt Melanoma Trial found that SLN biopsy of cervical nodal basins resulted in a lower rate of complications (2.4%) than biopsies of axillary (4.4%) or inguinal (8.1%) nodal basins.¹¹³

CASE CONTINUED

Lymphoscintigraphy indicates that the patient drains anterior to the left submandibular region and posterior to the left level V cervical nodes. The submandibular SLN has a 3.3-mm metastasis as shown by hematoxylin/eosin staining, and the level V SLNs

are tumor free as judged by hematoxylin/eosin staining and immunohistochemistry. The patient refuses a clinical trial.

What would you recommend as the next step in the treatment of this patient?

1. Observation
2. Adjuvant radiotherapy to the primary site only
3. Adjuvant radiotherapy to the primary site and anterior neck
4. Left modified radical neck dissection
5. Left modified radical neck dissection and left parotidectomy

The faculty recommends that the patient undergo a left modified radical neck dissection, consistent with NCCN guidelines advocating CLND for patients with a positive SLN.² The risk of non-SLN involvement in

patients with a positive SLN is about 25%. However, the presence of an SLN metastasis 2 mm or larger or Breslow thickness of 3 mm or greater increases this risk above 31%, or 40% if both factors are present.¹¹⁴

The addition of parotidectomy is controversial. The rationale in favor of this procedure is that lymph drainage has to traverse through the gland on its way from the anterior scalp to the submandibular and anterior cervical lymph nodes, and therefore it is possible that parotid lymph nodes may harbor some malignant cells. However, SLN biopsy in the parotid gland region is highly accurate; one study reported a false negative rate of only 3% (1 out of 35 patients).¹¹² Nevertheless, we recommend against an elective

parotidectomy unless an SLN in the parotid region contains melanoma. This avoids the potential morbidities associated with this procedure, including damage to the facial nerve and other cranial nerves.¹¹⁵

Case Continued: Further Treatment?

A completion left modified radical neck dissection is performed. Fifty-one nodes are removed, and 1 additional node is positive for metastatic melanoma (total of 2/54).

What would you recommend as the next step in locoregional management?

1. No further treatment
2. Adjuvant radiotherapy to the primary site only
3. Adjuvant radiotherapy to the cervical region only
4. Adjuvant radiotherapy to both the primary site and the cervical region

There are few clinical data to guide clinicians in this choice. The faculty recommends radiotherapy to both the primary site and cervical region for patients with DM, although they recognize that some clinicians may prefer irradiation to the cervical region alone.

Adjuvant Radiotherapy for Patients With Cervical Node Involvement

The overall rate of nodal basin recurrence for patients with metastatic melanoma who have undergone lymph node dissection is approximately 30% at 10 years.¹¹⁶ However, certain features increase this risk dramatically, including cervical node involvement, more than 3 positive lymph nodes, extracapsular extension, and node larger than 3 cm.^{116,117} The patient in this study has 2 of these characteristics (cervical involvement and node size >3 cm), each of which is associated with a 10-year recurrence rate of over 40%.¹¹⁶ He is therefore a good candidate for adjuvant radiotherapy.

Although clinical experience suggests that radiotherapy improves nodal control, to date there have

been no controlled randomized trials to verify this point. An ongoing phase 3 Trans-Tasman Radiation Oncology Group trial is comparing surgery alone vs surgery plus adjuvant radiotherapy in melanoma patients with resected macroscopic nodal metastases, but no data are available at this time.¹¹⁸

The only published comparison of neck dissection with or without nodal irradiation employed data from the Sydney Melanoma Unit, but this study was not randomized.¹¹⁹ Although radiotherapy was primarily reserved for patients with more extensive nodal involvement and a higher risk of recurrence, patients in the irradiated group had a regional recurrence rate of 6.5%, compared with 18.7% in the nonirradiated group.¹¹⁹ Other nonrandomized studies also suggest that radiotherapy improves locoregional control in patients with head and neck melanoma.¹²⁰⁻¹²² Radiotherapy of both primary and nodal sites may provide additional benefits. Researchers from the University of Texas M. D. Anderson Cancer Center conducted a retrospective review of medical records from 160 patients with cervical lymph node metastases who were treated with wide local excision of the primary lesion (when known) and neck dissection or local excision of the lymph node metastasis followed by adjuvant irradiation of the primary site and the ipsilateral lymph nodes.¹²¹ Thirteen patients (8%) experienced locoregional recurrence during the median follow up of 78 months, for a 10-year locoregional control rate of 92%. Distant disease occurred in 51% of patients, and the 10-year overall survival rate was 39%.¹²¹ These data indicate that adjuvant radiation to the primary site and cervical nodes results in excellent locoregional control. The impact of radiotherapy on distant disease and overall survival is less clear.

Patients with DM may be particularly good candidates for primary-site radiotherapy because of the high recurrence rates associated with this

form of melanoma, but, as noted previously, randomized trial data supporting this hypothesis are lacking. A retrospective review of DM patients, most (68%) of whom had lesions in the head and neck region, reported a local recurrence rate of 48% after initial surgery.¹²³ Of 15 patients who received radiotherapy after re-excision, none developed a subsequent local recurrence. In comparison, 4 of 7 patients who did not receive radiotherapy after re-excision (57%) developed another local recurrence.¹²³ However, Arora and colleagues reported excellent local control rates (4% recurrence at a mean follow up of 3.7 years) in patients with DM in the absence of radiotherapy and suggested that with careful attention to surgical margins, adjuvant radiotherapy may not be necessary.¹²⁴

Radiotherapy to the head and neck region is generally well tolerated. Common side effects include mild fibrosis and alterations in the irradiated skin (induration, loss of subcutaneous fat, or slight atrophy). Adverse events that require medical intervention (grade 2) are rare and include hearing loss, clinical hypothyroidism, wound breakdown, bone exposure, mild ear pain, and edema.^{121,122}

CONCLUSION

Head and neck melanomas, especially melanomas of the scalp and neck, appear to be associated with reduced survival rates compared with melanoma of other sites. DM, which occurs more often in the head and neck than at other sites, has a unique presentation and can be difficult to diagnose. The staging of head and neck melanomas is a challenge; lymphatic drainage patterns are complex and unpredictable, and can include problematic sites at which surgical interventions may lead to nerve damage and facial paralysis. Clinical experience suggests that radiotherapy may be helpful in controlling disease in patients with head and neck melanoma.

Barriers-to-Care for Patients With Melanoma: Special Care Issues—Pregnancy and People of Color

(continued from page 4)

had any effect on outcomes.⁴

Although this finding did not affect outcomes, Lens et al also documented that cutaneous melanoma lesions were thicker during the last trimester of pregnancy and postulated that pregnant women and their physicians may be less concerned about a changing mole because of the notion that nevi may darken and enlarge during pregnancy.⁴

Consequently, as at any age, early recognition of thin melanomas must be the goal when treating women with pigmented lesions during child-bearing age. And, pregnant women and their physicians must not be complacent and should seek advice from a dermatologist as soon as possible for any moles that change in appearance.

Management of Melanoma in Pregnancy

The management of melanoma in pregnant women is similar to that in the general population. Surgery is the definitive therapy for early-stage disease (AJCC Stage I–II) for all patients with melanoma and can be safely performed during pregnancy. However, the treatment of pregnant women with advanced disease (AJCC Stage III–IV) is not as clear because of concerns about the well-being of the fetus. Therefore, according to Leachman et al, “less-aggressive therapy may be preferable to avoid fetal side effects when more aggressive therapy offers little gain for the mother.”²

Melanoma and Family Planning

Schwartz et al address the issue of how long a prospective mother should wait to become pregnant after being treated for early-stage

melanoma. Noting that there are no set guidelines, the authors suggest that a decision “should be based on the risk of recurrence weighed against the age of the patient and the desire to get pregnant.”³ A woman with a thin melanoma at low risk of spread, for example, may have to wait for 2 years or less, while a woman with a deeper lesion at higher risk of spread may need to wait 3 to 5 years before considering pregnancy.

For women who have decided not to become pregnant, the use of oral contraceptives or hormonal replacement does not appear to increase the risk of developing melanoma.⁵ However, some physicians may recommend barrier methods of contraception if the woman is at all concerned.

Melanoma and Ethnic Differences

In a recent study of almost 50,000 patients with melanoma, Cormier et al documented the differences in melanoma incidence per 100,000 persons for a number of ethnic groups, including 18.4 for white Americans compared with 2.3 for Hispanic Americans, 0.8 for African Americans, 1.6 for American Indians, and 1.0 for Asian Americans.⁶ Although melanoma was significantly less common in the nonwhite groups, these populations were more likely than whites to be diagnosed with an advanced stage of melanoma. Compared with whites, the other ethnic groups were 2.4 to 4.2 times more likely to present with stage IV disease.

In an earlier study with similar incidence results, Cress and Holly documented that Hispanic American,

Asian American, and African American patients were more likely than non-Hispanic white Americans to have been diagnosed with acral lentiginous melanoma.⁷ Occurring on the palms, the soles, or beneath the nail bed, this subtype of melanoma accounts for 2% to 8% of melanoma in non-Hispanic White Americans and from 29% to 72% of cases of melanoma in nonwhite individuals. And, Bellows et al documented a median survival time of 45 months for African Americans with cutaneous lesions compared with 135 months for whites, a threefold difference.

Role of Dermatologists

Aside from being attentive to the differences in melanoma presentation in dark-skinned individuals and providing appropriate treatment, dermatologists should provide leadership for primary and secondary prevention efforts, including local awareness campaigns for both patients and primary care providers.

Many of the current campaigns for skin cancer prevention focus on fair-skinned individuals who are at greatest risk of sunburn. However, in many parts of the United States, including areas with high rates of sun exposure (such as California, Texas, and Florida), nonwhite Hispanic Americans and Asian Americans may soon become a majority of the population. Prevention should include educational programs not only to encourage the use of sun protection by dark-skinned people but also to promote regular skin self-examinations that include the hands, feet, nails and non-sun exposed areas, and to encourage prompt visits to a dermatologist if a new, changing, concerning or outlier lesion is noted.

References

- Halpern AC, Mandal SK. Role of dermatologists in treating melanoma. *J Natl Compr Canc Net*. 2006;4:695-702.
- Leachman SA, Jackson R, Eliason MJ, et al. Management of melanoma during pregnancy. *Dermatol Nurs*. 2007;19:145-152.
- Schwartz JL, Mozurkewich EL, Johnson TM. Current management of patients with melanoma who are pregnant, want to get pregnant, or do not want to get pregnant. *Cancer*. 2003;97:2130-2133.
- Lens MB, Rosdahl I, Ahlborn A, et al. Effect of pregnancy on survival in women with cutaneous malignant melanoma. *J Clin Oncol*. 2004;22:4369-4375.
- Karagas MR, Stukel TA, Dykes J, et al. A pooled analysis of 10 case-control studies of melanoma and oral contraceptive use. *Br J Cancer*. 2002;86:1085-1092.
- Cormier JN, Xing Y, Ding M, et al. Ethnic differences among patients with cutaneous melanoma. *Arch Intern Med*. 2006;166:1907-1914.
- Cress RD, Holly EA. Incidence of melanoma among non-Hispanic whites, Hispanics, Asians, and blacks: an analysis of California registry data, 1988-93. *Cancer Causes Control*. 1997;8:246-252.

Barriers-to-Care for Patients With Melanoma: Lack of Coordinated Management of Brain Metastases

(continued from page 4)

management of suspected melanoma brain metastases, dermatologists should counsel patients about the role of various therapeutic options for their treatment. Providing such information will help patients become better advocates for their own health.

Potential treatment options include surgical resection for solitary lesions, stereotactic radiosurgery, whole-brain radiation therapy (WBRT), and chemotherapy.

Surgical Resection

Surgical resection may be effective in melanoma patients with a single brain lesion (or a limited number of accessible lesions) and little or no extracranial disease. A number of studies comparing surgery plus WBRT vs WBRT alone support the benefit of surgery in these patients.

Both Sampson et al² and Zacest et al⁴ noted that long-term survival (more than 3 years) occurs in patients with a single surgically treated brain metastasis in the absence of extracranial disease. And, Wronski and Arbit⁵ concluded that "Although melanoma metastatic to the brain carries a foreboding prognosis, patients who do not display preoperative neurological deficits, harbor a single lesion situated supratentorially, and have no lung or visceral metastases may derive significant palliative benefit from surgical resection of brain metastases."

Stereotactic Radiosurgery

Stereotactic radiosurgery (SRS) is a single high-dose radiation treatment aimed specifically at a target lesion using a linear accelerator or gamma knife. SRS may be an appropriate option for patients with limited or absent systemic disease who have an unresectable solitary lesion, multiple inaccessible lesions, and those who

refuse surgery or are not good surgical candidates.

As reported in the oncology and neurosurgery literature, there is a great deal of experience with SRS in patients with melanoma brain metastases. Many of these studies indicate that SRS provides local control rates comparable to those for neurosurgery. For example, in 1999, Lavine and colleagues⁶ reported that "gamma knife radiosurgery seems to be a relatively safe, noninvasive, palliative therapy, halting or reversing neurological progression in 77.8% of treated patients." The authors concluded that "The survival rate matches or exceeds those previously reported for surgery and other forms of radiotherapy."

In a more recent study, Mathieu et al⁷ reported on 244 patients who had radiosurgery for the management of 754 metastatic lesions. Noting that sustained local control was achieved in 86.2% of tumors and 71.4% of the patients improved or remained clinically stable, the authors concluded that "Gamma knife radiosurgery for malignant melanoma brain metastases is safe and effective and provides a high rate of durable local control."

Whole-Brain Radiation Therapy

WBRT may be used as adjuvant therapy following both surgical resection and SRS with a goal of treating residual malignant cells at the site of resection and elsewhere in the brain. Although it is used often, the role of adjuvant WBRT following surgical resection or radiosurgery has not been proven. Several authors^{8,9} noted that WBRT combined with SRS did not improve survival or local tumor control. And, according to Major and Samlowski,³ the role of WBRT following either complete surgical resection of a brain lesion or SRS is controversial.

WBRT may also be used for

patients who are not appropriate candidates for surgery or SRS because of poor performance status or the location or number of their brain lesions. Even with treatment, the outcome for these patients is poor. As part of their large retrospective study, Fife et al¹⁰ reported that patients who underwent WBRT had a median survival of 3.4 months, compared with a median survival of 2.1 months for patients receiving only supportive care.

Chemotherapy

Melanoma is relatively resistant to chemotherapy, and systemic treatment for brain metastases has generally not been effective. Many of the frequently used treatment regimens for extracranial melanoma, including dacarbazine and biologic therapy (interferon and interleukin) have limited activity in the brain.

Much of the recent chemotherapy literature relating to melanoma brain metastases has focused on temozolomide, an orally active alkylating agent that crosses the blood-brain barrier. Responses to temozolomide have been documented with temozolomide alone and in combination with thalidomide and radiation therapy. Commenting on several of these recent studies, Majer and Samlowski³ conclude that "The effectiveness of temozolomide in treatment of established brain metastasis, however, has not been impressive."

Multidisciplinary Approach

Ideally, patients should be managed by a multidisciplinary team consisting of a medical oncologist, a neurosurgeon, a radiation oncologist, and a neurologist who work closely together to assure that patients receive appropriate care.

Given the morbidity and mortality of melanoma brain lesions and the increasing availability of more successful interventions, aggressive

screening in high-risk patients who do not have neurologic symptoms may be warranted. Early diagnosis and an aggressive treatment regimen from a team of knowledgeable pro-

fessionals may improve the outcome for patients with melanoma brain metastases.

Unfortunately, many patients in community settings may have lim-

ited access to such coordinated services. To better help their patients with suspected brain metastases, dermatologists should identify appropriate referral sources.

References

1. Skibber JM, Soong SJ, Austin L, et al. Cranial irradiation after surgical excision of brain metastases in melanoma patients. *Ann Surg Oncol* 1996;3:118-123.
2. Sampson JH, Carter JH Jr, Friedman AH, Seigler HF. Demographics, prognosis, and therapy in 702 patients with brain metastases from malignant melanoma. *J Neurosurg* 1998; 88:11-20.
3. Majer M, Samlowski WE. Management of metastatic melanoma patients with brain metastases. *Curr Oncol Rep* 2007;9:411-416.
4. Zacest AC, Besser M, Stevens G, et al. Surgical management of cerebral metastases from melanoma: outcome in 147 patients treated at a single institution over two decades. *J Neurosurg* 2002;96:552-558.
5. Wronski M, Arbit E. Surgical treatment of brain metastases from melanoma: a retrospective study of 91 patients. *J Neurosurg* 2000;93:9-18.
6. Lavine S, Petrovich Z, Cohen-Gadol AA, et al. Gamma knife radiosurgery for metastatic melanoma: an analysis of survival, outcome, and complications. *Neurosurgery* 1999;44:59-66.
7. Mathieu D, Kondziolka D, Cooper PB, et al. Gamma knife radiosurgery in the management of malignant melanoma brain metastases. *Neurosurgery* 2007;60:471-482.
8. Mori Y, Kondziolka D, Flickinger JC, et al. Stereotactic radiosurgery for cerebral metastatic melanoma: factors affecting local disease control and survival. *Int J Radiat Oncol Biol Phys* 1998;42:581-589.
9. Radbill AE, Fiveash JF, Falkenberg ET, et al. Initial treatment of melanoma brain metastases using gamma knife radiosurgery: an evaluation of efficacy and toxicity. *Cancer* 2004;101:825-833.
10. Fife KM, Colman MH, Stevens GN, et al. Determinants of outcome in melanoma patients with cerebral metastases. *J Clin Oncol* 2004;22:1293-1300.

CE Questions

Please answer each question in the space provided on page 24.

1. Compared with nonpregnant women with melanoma, pregnant women with melanoma have:
 - A. Similar survival rates
 - B. A greater likelihood of metastatic disease
 - C. Unique prognostic factors
 - D. A higher rate of head and neck melanoma
2. With respect to oral contraceptives and hormone replacement therapy, case-control studies have found that:
 - A. Both increase the risk of melanoma
 - B. Only oral contraceptives increase the risk of melanoma
 - C. Only hormone replacement therapy increases the risk of melanoma
 - D. Neither increases the risk of melanoma
3. When excising in-transit lesions, clinicians should use:
 - A. The same margins recommended for primary-site excisions
 - B. Wider margins because of the risk of local recurrence
 - C. Narrower margins because in-transit lesions are typically discrete nodules
 - D. In-transit lesions should never be excised
4. A complete response to ILP:
 - A. Usually lasts at least 5 years
 - B. Is a significant predictor of survival
 - C. Is more likely to occur in patients treated with dacarbazine
 - D. Occurs, on average, in fewer than 10% of treated patients
5. Patients with MUP:
 - A. Are more likely to be women than men
 - B. Often present with lymph node involvement
 - C. Rarely report a history of spontaneously regressed lesions
 - D. Seldom have a single metastatic lymph node
6. Disease-free and overall survival in patients with MUP are similar to those in patients with what stage of melanoma?
 - A. Stage I
 - B. Stage II
 - C. Stage III
 - D. Stage IV
7. Patients with head and neck melanoma typically have:
 - A. Higher survival rates than those with melanoma at other sites
 - B. Multiple sentinel nodes
 - C. Predictable lymphatic drainage patterns
 - D. A high rate of nodal involvement
8. Desmoplastic melanoma is NOT associated with:
 - A. Thicker lesion(s) at initial presentation
 - B. An older patient population
 - C. A large proportion of nonpigmented lesions
 - D. Reduced survival rates
9. According to Majer and Samlowski, current treatment strategies for melanoma brain metastases result in poor outcomes, with a median survival of:
 - A. 1-2 weeks
 - B. 2-4 months
 - C. 5-7 months
 - D. 1-2 years
10. Potential treatment options for melanoma brain metastases include all of the following EXCEPT:
 - A. Stereotactic radiosurgery
 - B. Whole-brain radiation therapy
 - C. Chemotherapy
 - D. High-dose interferon alfa-2b therapy

Evaluation Form

Please use the scale below in answering these questions. Fill in the circle completely. You may use pen or pencil to fill in the circles.

- | | Very Low | Low | Moderate | High | Very High | | Very Low | Low | Moderate | High | Very High |
|---|-----------------------|-----------------------|-----------------------|-----------------------|-----------------------|--|-----------------------|-----------------------|-----------------------|-----------------------|-----------------------|
| 1. To what extent were the following educational objectives achieved? | | | | | | 3. To what extent was the content of the program relevant to your practice or professional responsibilities? | | | | | |
| A. Address treatment issues in melanoma with complicating features or special circumstances, including pregnancy, in-transit melanoma, unknown primaries, or head and neck melanoma | <input type="radio"/> | <input type="radio"/> | <input type="radio"/> | <input type="radio"/> | <input type="radio"/> | 4. To what extent did the program enhance your knowledge of the subject area? | <input type="radio"/> | <input type="radio"/> | <input type="radio"/> | <input type="radio"/> | <input type="radio"/> |
| B. Discuss the diagnostic pitfalls and available treatment modalities for melanoma in pregnant women | <input type="radio"/> | <input type="radio"/> | <input type="radio"/> | <input type="radio"/> | <input type="radio"/> | 5. To what extent did the program change the way you think about clinical care and/or professional responsibilities? | <input type="radio"/> | <input type="radio"/> | <input type="radio"/> | <input type="radio"/> | <input type="radio"/> |
| C. Describe the prognostic features and available treatment options for melanomas in problematic sites, including in-transit melanoma, head and neck melanoma, melanoma in pregnant patients, and metastatic melanoma with unknown primary origin | <input type="radio"/> | <input type="radio"/> | <input type="radio"/> | <input type="radio"/> | <input type="radio"/> | 6. To what extent will you make a change in your practice and/or professional responsibilities as a result of your participation in this educational activity? | <input type="radio"/> | <input type="radio"/> | <input type="radio"/> | <input type="radio"/> | <input type="radio"/> |
| D. Compare and contrast the prognostic features of melanoma with unknown primary versus other types of metastatic melanoma | <input type="radio"/> | <input type="radio"/> | <input type="radio"/> | <input type="radio"/> | <input type="radio"/> | 7. To what extent did the activity present scientifically rigorous, unbiased, and balanced information? | <input type="radio"/> | <input type="radio"/> | <input type="radio"/> | <input type="radio"/> | <input type="radio"/> |
| 2. To what extent were you satisfied with the overall quality of the educational activity? | <input type="radio"/> | <input type="radio"/> | <input type="radio"/> | <input type="radio"/> | <input type="radio"/> | 8. To what extent was the presentation free of commercial bias? | <input type="radio"/> | <input type="radio"/> | <input type="radio"/> | <input type="radio"/> | <input type="radio"/> |

Answer Posttest Questions Here

1. 2. 3. 4. 5. 6. 7. 8. 9. 10.

If you wish to receive credit for this activity, please fill in your name and address and fax to:

University of Pittsburgh Center for Continuing Education at 412-647-8222, or mail to:
UPMC Center for Continuing Education, Medical Arts Building, Suite 220, 200 Lothrop Street, Pittsburgh, PA 15213

I have completed the activity and claim _____ credit hours

Request for Credit

Name: _____ Degree _____
 Address: _____ City, State, ZIP: _____
 Organization: _____ Specialty: _____ Last 5 Digits of SSN: _____
 Telephone Number: _____ Fax: _____ E-mail _____

MELANOMA CARE OPTIONS™

DECEMBER 2007

Issue 3: Dermatology Edition



PharmAdura, LLC
523 Route 303
Orangeburg, NY 10962